



ALBERT EINSTEIN
HOSPITAL ISRAELITA

O papel dos exames de imagem no rastreamento e estadiamento no câncer de próstata: o exame certo para o paciente certo

Ronaldo Hueb Baroni

Chefe do Grupo de Radiologia Abdominal e Coordenador Médico do Setor de Ressonância Magnética do Hospital Israelita Albert Einstein

Rastreamento de tumor de próstata hoje...

- TR alterado
- PSA: $> 2,5$ ng/ml

BIÓPSIA DE PRÓSTATA

- 1 milhão de biópsias prostáticas anuais são realizadas nos EUA
- A técnica randomizada em sextantes ainda é a mais utilizada (até 16 fragmentos).
- Biópsia prostática randomizada pode não detectar tumor em até 30-60 % dos casos
- Até 50% dos CaP diagnosticados não são clinicamente significantes



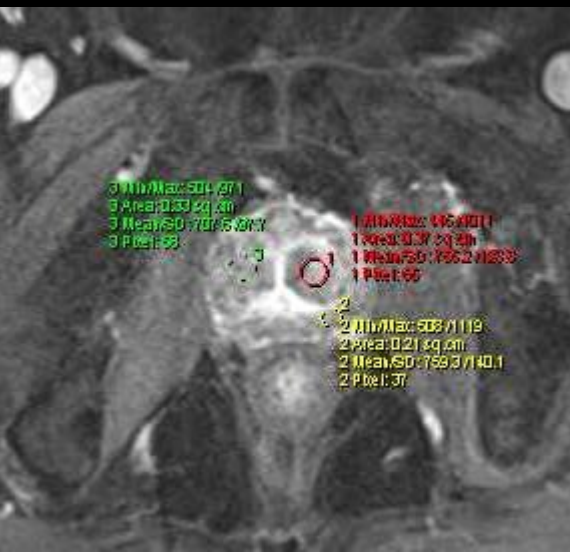
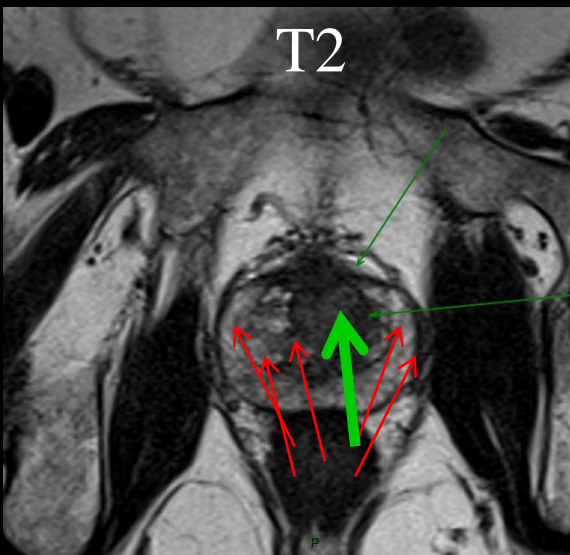
Estadio clínico T1 c
Densidade PSA < 0.15 ng/mL
Sem Gleason 4 ou 5
Até 3 fragmentos < 50%

J Urol 2002;167:2435-2439

J Urol 2001;165:1554-1559

J Urol, 2003;169(1) 12-19.

RM MULTIPARAMÉTRICA



AP: Adenoca Gleason 8 (5 + 3)

available at www.sciencedirect.com
journal homepage: www.europeanurology.com

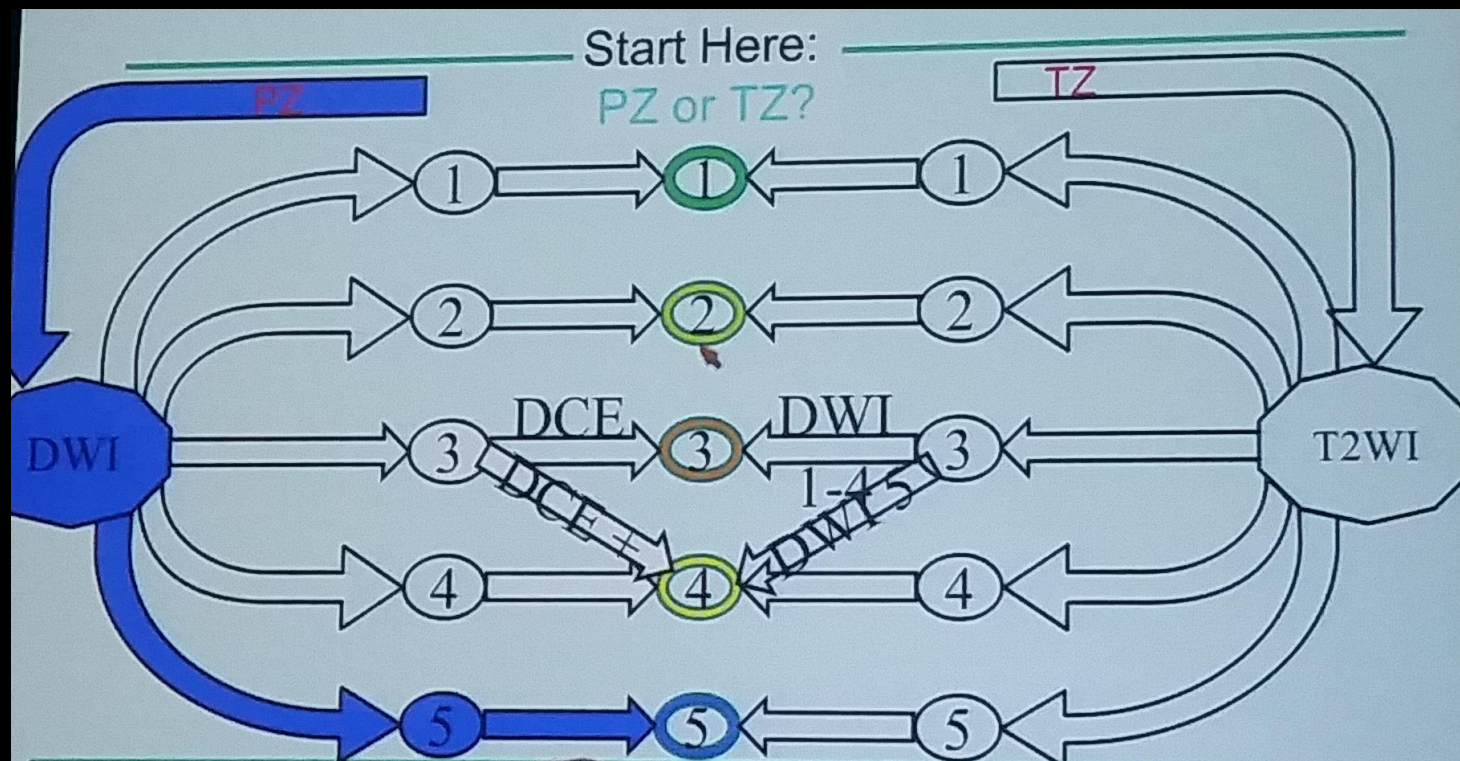


Platinum Priority – Prostate Cancer

Editorial by Jelle O. Barentsz, Jeffrey C. Weinreb, Sadhna Verma et al on pp. 41–49 of this issue

PI-RADS Prostate Imaging – Reporting and Data System: 2015, Version 2

Jeffrey C. Weinreb^{a,†,*}, Jelle O. Barentsz^{b,†}, Peter L. Choyke^c, Francois Cornud^d, Masoom A. Haider^e, Katarzyna J. Macura^f, Daniel Margolis^g, Mitchell D. Schnall^h, Faina Shternⁱ, Clare M. Tempny^j, Harriet C. Thoeny^k, Sadna Verma^l



Paciente 64 anos, elevação PSA, toque normal

	07/04/2011	21/08/2013
PSA total (ng/ml)	7,2	14,2
%PSA livre	8	8

Biopsia prévia negativa (08/06/2012)

PEÇAS RADICAIS E PUNÇÕES

Exame Anatomopatológico

Espécimes e Procedimentos

Próstata, biópsias seriadas por agulha

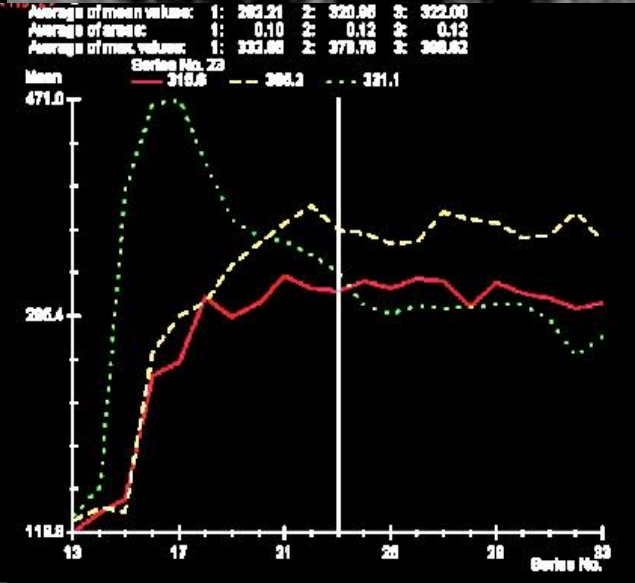
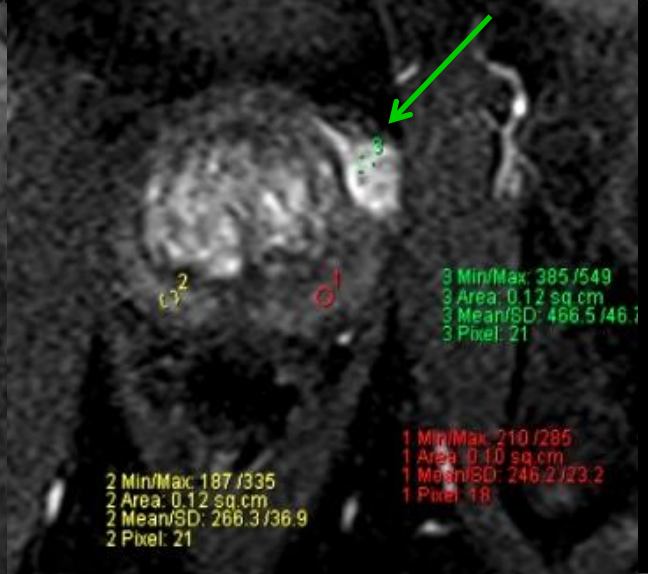
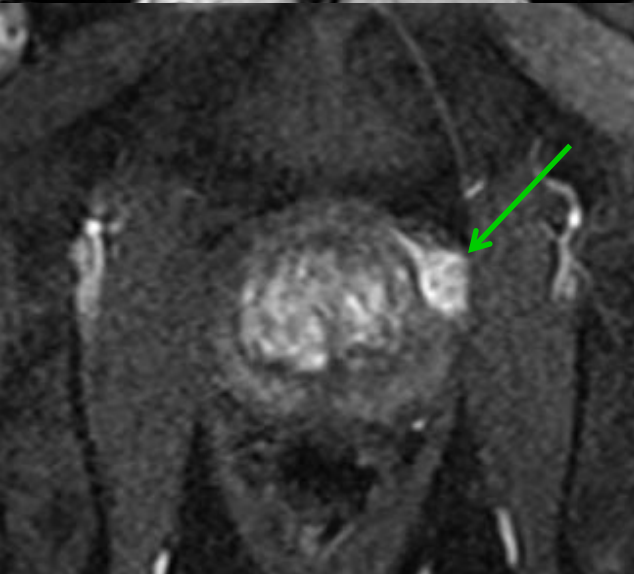
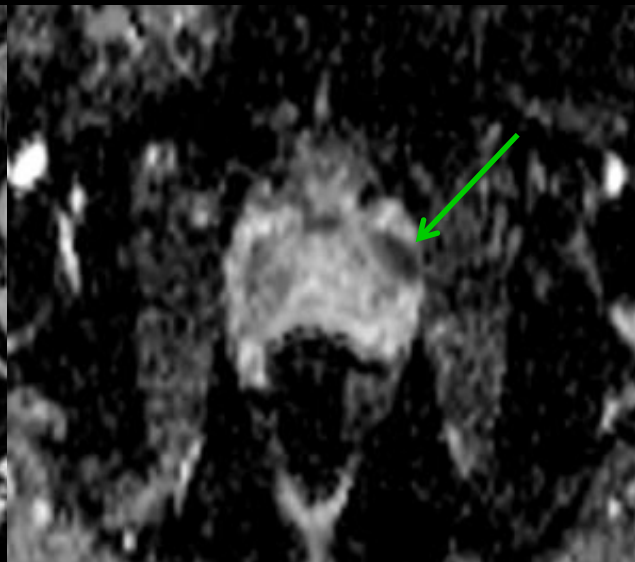
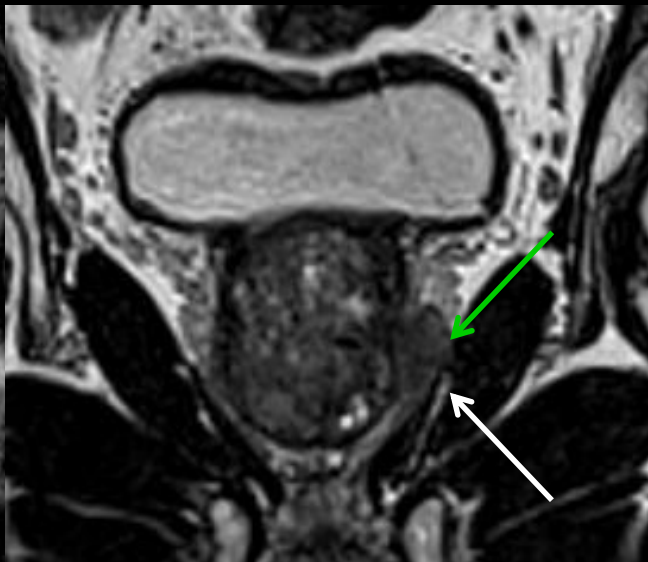
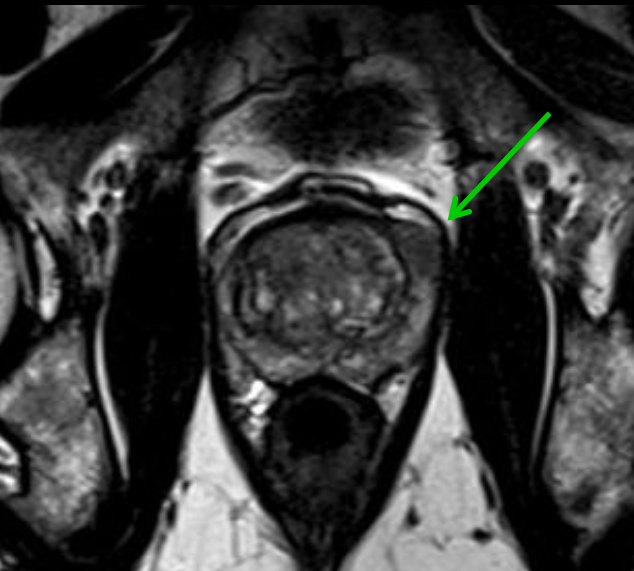
Microscopia e Conclusões

Diagnósticas

Negativo para neoplasia (todas as amostras)

Atrofia glandular multifocal

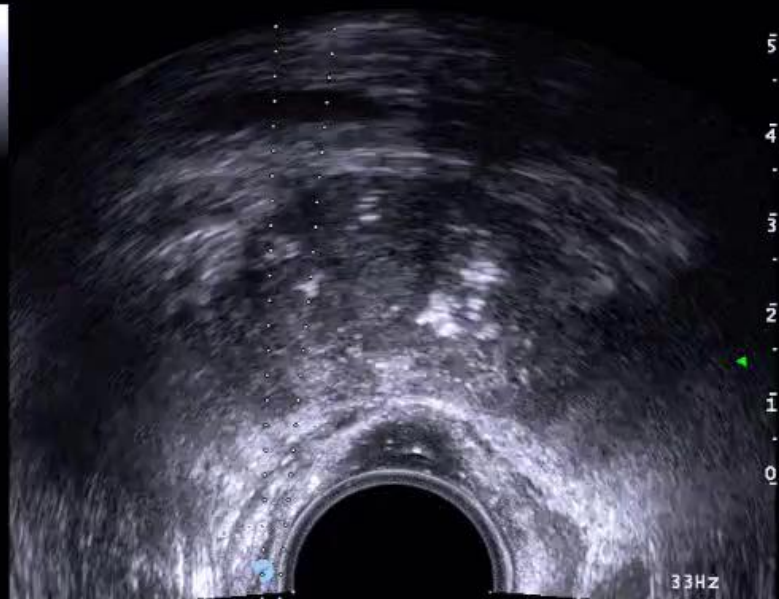
Prostatite crônica não específica com focos de atividade aguda



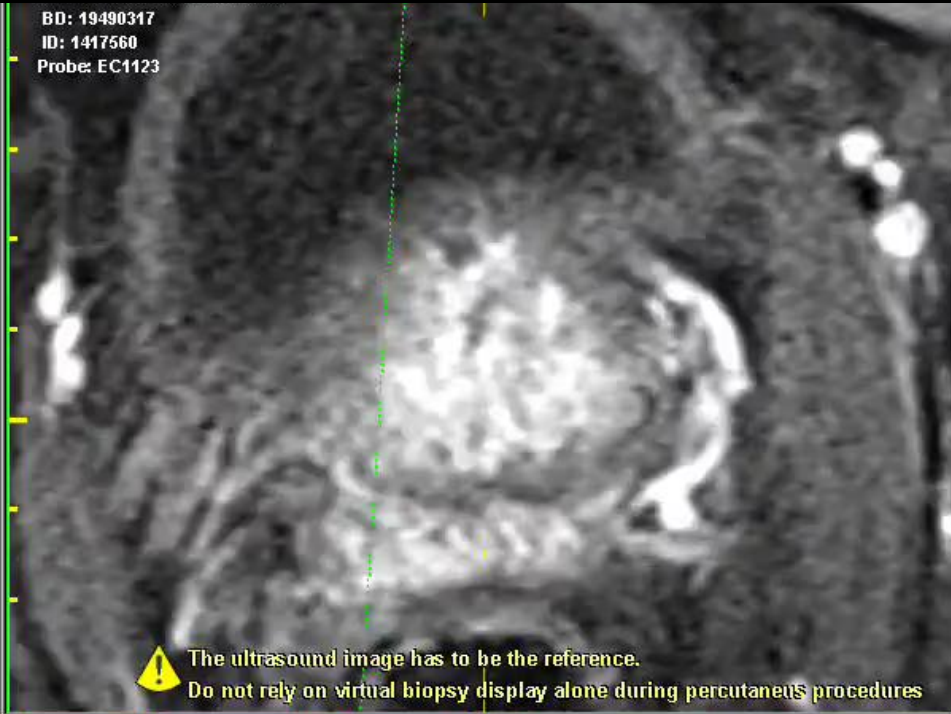PIRADS 5

PRC 11/1/2 PRS 8
PST 0 C 2

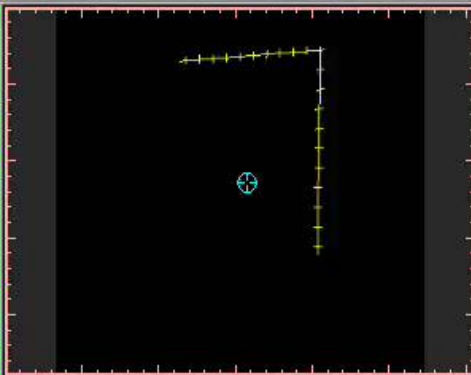
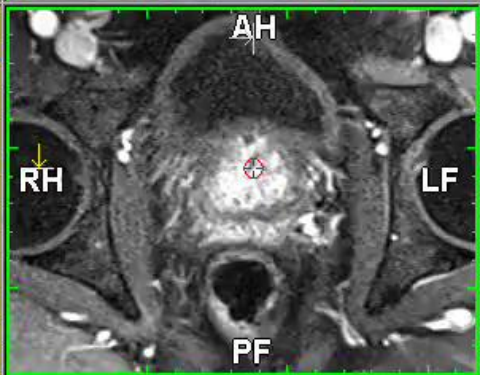
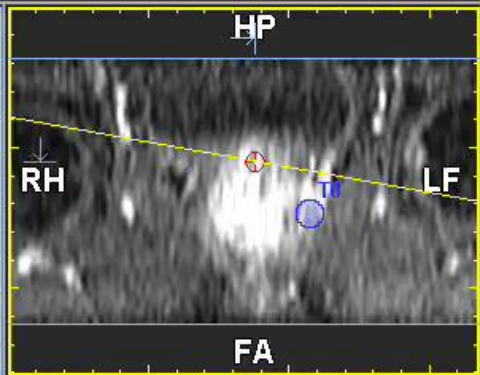
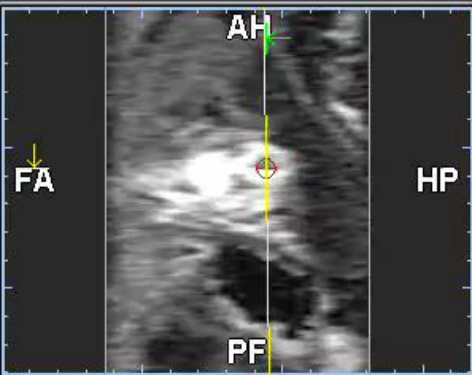
C1123



BD: 19490317
ID: 1417560
Probe: EC1123



! The ultrasound image has to be the reference.
Do not rely on virtual biopsy display alone during percutaneous procedures



- **BIÓPSIA (04/09/2013)**
Adenocarcinoma usual
- Gleason 8 (4+4)
ZPE ML 23%,
Nódulo lobo esquerdo 50%

BIÓPSIA DE PRÓSTATA GUIADA POR US

[Laudo](#) [Laudo + Imagens chaves](#) [Estudo completo](#) [Instruções](#)

Data de liberação: 04/09/2013

PEÇAS RADICAIS E PUNÇÕES
Exame Anatomopatológico
Passagem: 11329995

Dados Clínicos

Aumento do PSA.

Espécimes e Procedimentos

Próstata, biópsias

Microscopia e Conclusões
Diagnósticas

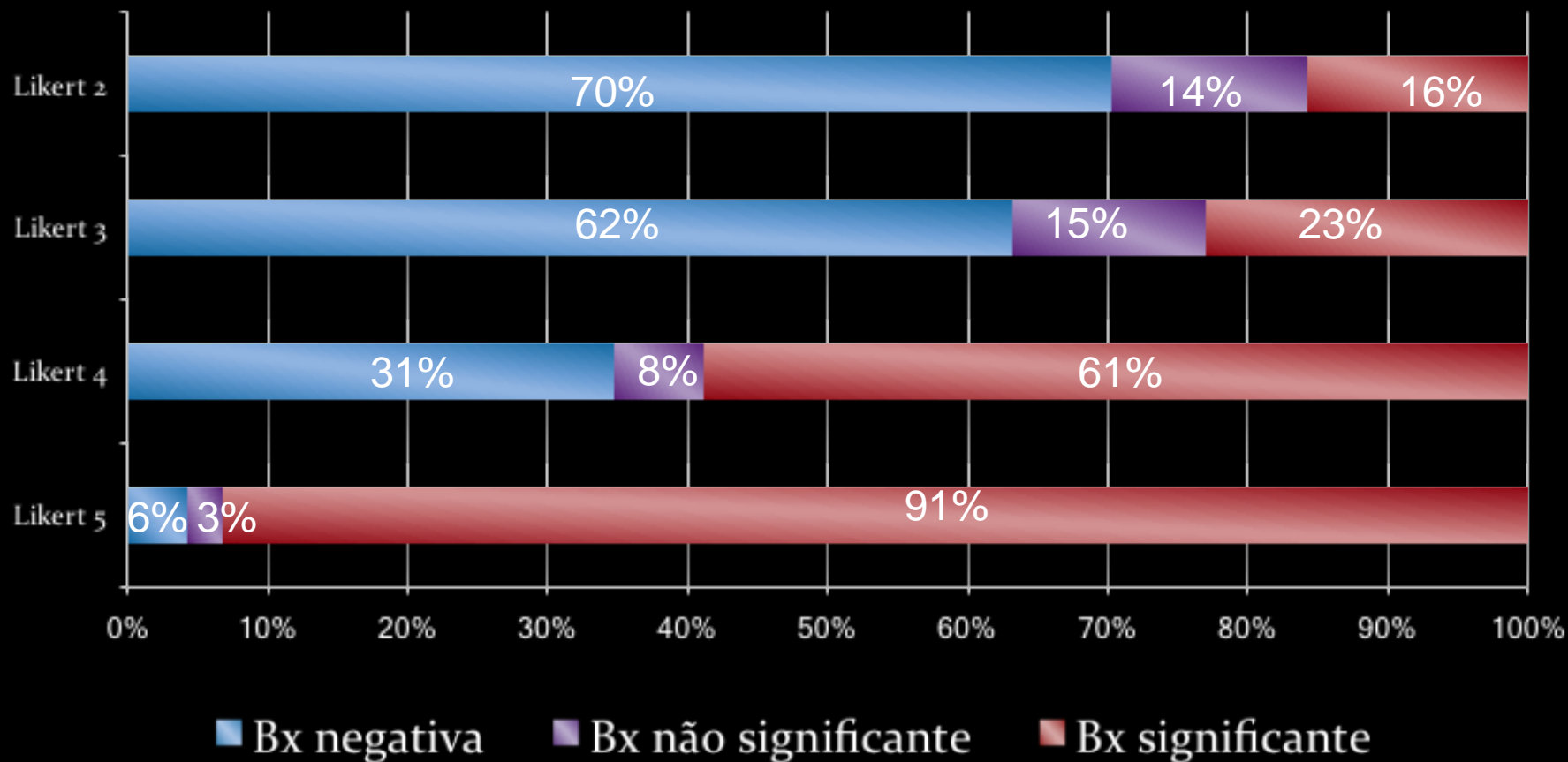
Adenocarcinoma acinar usual da próstata de Gleason 8 (4+4), comprometendo:
Zona periférica esquerda, terço médio lateral (item 11): extensão linear máxima de 1,0 mm; cerca de 23% dos cilindros prostáticos;

Adenocarcinoma acinar usual da próstata de Gleason 7 (4+3), comprometendo:
Zona periférica direita, ápice medial (item 5): extensão linear máxima de 1,0 mm; cerca de 8% dos cilindros prostáticos;
Zona periférica esquerda, base medial (item 8): extensão linear máxima de 2,3 mm; cerca de 13% dos cilindros prostáticos;
Zona periférica esquerda, ápice medial (item 12): extensão linear máxima de 1,9 mm; cerca de 12% dos cilindros prostáticos;
Nódulo de lobo esquerdo (item 14): extensão linear máxima de 5,5 mm; cerca de 50% dos cilindros prostáticos;

Dados adicionais:
Porcentagem de cilindros prostáticos comprometidos pela neoplasia: 37% (07 em total)

Infiltração perineural: não detectada;
Infiltração angiolímfática: não detectada;
Extensão extra-prostática: não detectada;
Fragmentação de cilindros prostáticos: ausente.

Mmp + biópsia com fusão (1003 pacientes agosto 2013 – fevereiro 2018)



Critério de Epstein

Original Investigation

Comparison of MR/Ultrasound Fusion-Guided Biopsy With Ultrasound-Guided Biopsy for the Diagnosis of Prostate Cancer

M. Minhaj Siddiqui, MD; Soroush Rais-Bahrami, MD; Baris Turkbey, MD; Arvin K. George, MD; Jason Rothwax, BS; Nabeel Shakir, BS; Chinonyerem Okoro, BS; Dima Raskolnikov, BS; Howard L. Parnes, MD; W. Marston Linehan, MD; Maria J. Merino, MD; Richard M. Simon, DSc; Peter L. Choyke, MD; Bradford J. Wood, MD; Peter A. Pinto, MD

JAMA January 27, 2015 Volume 313, Number 4

Table 2. Performance of Different Biopsy Approaches in the Detection of Intermediate- to High-Risk Prostate Cancer on Whole-Gland Prostatectomy Specimen

	Targeted MR/Ultrasound Fusion Biopsy	Standard Extended-Sextant Biopsy	Combined Biopsy
Sensitivity, % (95% CI)	77 (67-84)	53 (43-63)	85 (76-91)
Specificity, % (95% CI)	68 (57-78)	66 (54-76)	49 (37-60)
Negative predictive value, % (95% CI)	70 (58-80)	53 (43-63)	73 (58-84)
Positive predictive value, % (95% CI)	75 (65-83)	66 (54-76)	67 (58-75)
Accuracy, % (95% CI)	73 (70-76)	59 (55-63)	69 (65-72)
AUC (95% CI)	0.73 (0.66-0.79)	0.59 (0.52-0.67)	0.67 (0.60-0.74)
P value of comparison with targeted MR/ultrasound biopsy		.005	.04

Abbreviations: AUC, area under the curve; MR, magnetic resonance.

UROGENITAL

Incremental diagnostic value of targeted biopsy using mpMRI-TRUS fusion *versus* 14-fragments prostatic biopsy: a prospective controlled study

Guilherme C. Mariotti¹ · Priscila M. Falsarella^{1,2} · Rodrigo G. Garcia¹ · Marcos R. G. Queiroz¹ · Gustavo C. Lemos³ · Ronaldo H. Baroni⁴

Table 3 Comparison of biopsy results according to the RB vs. FB protocols

Random biopsy (RB)	Fusion biopsy (FB)			Total
	Negative	Clinically non-significant disease	Clinically significant disease	
Negative	38 (38.0%)	1 (1.0%) ^a	5 (5.0%) ^a	44 (44.0%)
Clinically non-significant disease	6 (6.0%) ^b	5 (5.0%)	5 (5.0%) ^a	16 (16.0%)
Clinically significant disease	3 (3.0%) ^b	3 (3.0%) ^b	34 (34.0%)	40 (40.0%)
Total	47 (47.0%)	9 (9.0%)	33 (35.1%)	100 (100.0%)

American Urological Association (AUA) Society of Abdominal Radiology (SAR) Joint Consensus Statement

PROSTATE MRI AND MRI-TARGETED BIOPSY IN PATIENTS WITH PRIOR NEGATIVE BIOPSY

**Collaborative Initiative of the American Urological Association and the
Society of Abdominal Radiology's Prostate Cancer Disease-Focused Panel**

WORKGROUP MEMBERS

SAR: Andrew B. Rosenkrantz, MD; Sadhna Verma, MD; Peter Choyke, MD; Steven C. Eberhardt, MD; Masoom A. Haider, MD; Daniel J. Margolis, MD

AUA: Samir S. Taneja, MD; Krishnanath Gaitonde, MD; Scott E. Eggener, MD; Leonard S. Marks, MD; Peter Pinto, MD; Geoffrey A. Sonn, MD

CONSENSUS STATEMENTS

- Following an initial negative biopsy, there is an ongoing need for strategies to improve patient selection for repeat biopsy as well as the diagnostic yield from repeat biopsies.
- Many options exist for men with a previously negative biopsy.
- If a biopsy is recommended, prostate MRI and subsequent MRI-targeted cores appear to facilitate the detection of CS disease over standardized repeat biopsy.
- Thus, when high-quality prostate MRI is available, it should be strongly considered in any patient with a prior negative biopsy who has persistent clinical suspicion for prostate cancer and who is undergoing a repeat biopsy.

Diagnostic accuracy of multi-parametric MRI and TRUS biopsy in prostate cancer (PROMIS): a paired validating confirmatory study



Hashim U Ahmed*, Ahmed El-Shater Bosaily*, Louise C Brown*, Rhian Gabe, Richard Kaplan, Mahesh K Parmar, Yolanda Collaco-Moraes, Katie Ward, Richard G Hindley, Alex Freeman, Alex P Kirkham, Robert Oldroyd, Chris Parker, Mark Emberton, and the PROMIS study group†



Summary

Background Men with high serum prostate specific antigen usually undergo transrectal ultrasound-guided prostate biopsy (TRUS-biopsy). TRUS-biopsy can cause side-effects including bleeding, pain, and infection. Multi-parametric magnetic resonance imaging (MP-MRI) used as a triage test might allow men to avoid unnecessary TRUS-biopsy and improve diagnostic accuracy.

Methods We did this multicentre, paired-cohort, confirmatory study to test diagnostic accuracy of MP-MRI and TRUS-biopsy against a reference test (template prostate mapping biopsy [TPM-biopsy]). Men with prostate-specific antigen concentrations up to 15 ng/mL, with no previous biopsy, underwent 1.5 Tesla MP-MRI followed by both TRUS-biopsy and TPM-biopsy. The conduct and reporting of each test was done blind to other test results. Clinically significant cancer was defined as Gleason score $\geq 4+3$ or a maximum cancer core length 6 mm or longer. This study is registered on ClinicalTrials.gov, NCT01292291.

Findings Between May 17, 2012, and November 9, 2015, we enrolled 740 men, 576 of whom underwent 1.5 Tesla MP-MRI followed by both TRUS-biopsy and TPM-biopsy. On TPM-biopsy, 408 (71%) of 576 men had cancer with 230 (40%) of 576 patients clinically significant. For clinically significant cancer, MP-MRI was more sensitive (93%, 95% CI 88–96%) than TRUS-biopsy (48%, 42–55%; $p < 0.0001$) and less specific (41%, 36–46% for MP-MRI vs 96%, 94–98% for TRUS-biopsy; $p < 0.0001$). 44 (5.9%) of 740 patients reported serious adverse events, including 8 cases of sepsis.

Interpretation Using MP-MRI to triage men might allow 27% of patients avoid a primary biopsy and diagnosis of 5% fewer clinically insignificant cancers. If subsequent TRUS-biopsies were directed by MP-MRI findings, up to 18% more cases of clinically significant cancer might be detected compared with the standard pathway of TRUS-biopsy for all. MP-MRI, used as a triage test before first prostate biopsy, could reduce unnecessary biopsies by a quarter. MP-MRI can also reduce over-diagnosis of clinically insignificant prostate cancer and improve detection of clinically significant cancer.

Lancet 2017; 389: 815–22

Published [Online](#)

January 19, 2017

[http://dx.doi.org/10.1016/](http://dx.doi.org/10.1016/S0140-6736(16)32401-1)

[S0140-6736\(16\)32401-1](http://dx.doi.org/10.1016/S0140-6736(16)32401-1)

See [Comment](#) page 767

*These authors contributed equally

†For a complete list of members of the PROMIS study group see appendix

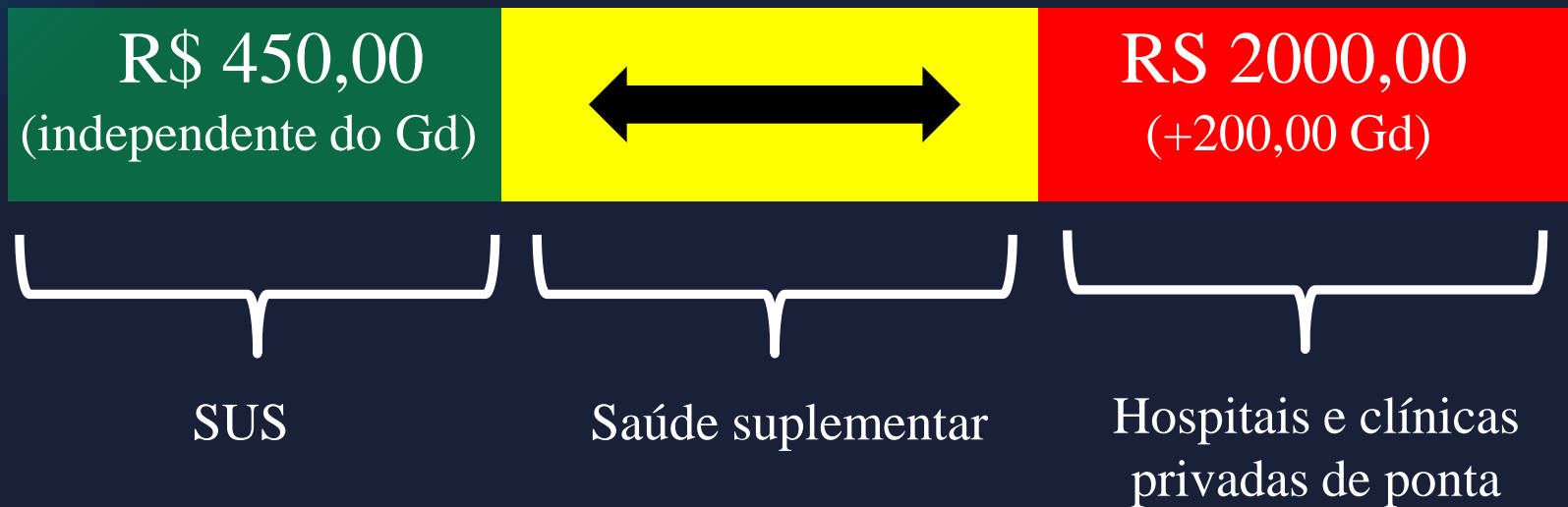
Division of Surgery and Interventional Science, Faculty of Medical Sciences, University College London, London, UK (H Ahmed FRCS, A El-Shater Bosaily MBBCh, Prof M Emberton FRCS); Department of Urology, UCLH NHS Foundation Trust, London, UK (H U Ahmed, A El-Shater Bosaily, Prof M Emberton); Department of Academic Urology, Royal Marsden Hospital, Sutton, UK (C Parker FRCS); MRC Clinical Trials Unit at UCL, London, UK (L C Brown PhD, R G Hindley FRCS)

Are Dynamic Contrast-Enhanced Images Necessary for Prostate Cancer Detection on Multiparametric Magnetic Resonance Imaging?

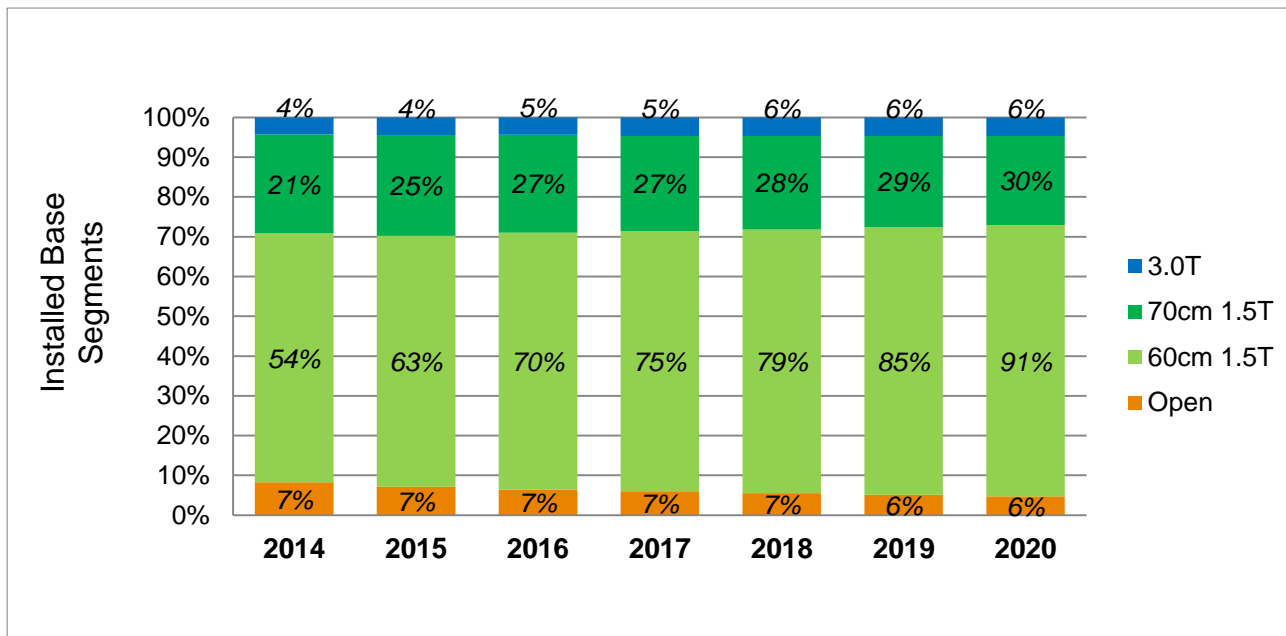
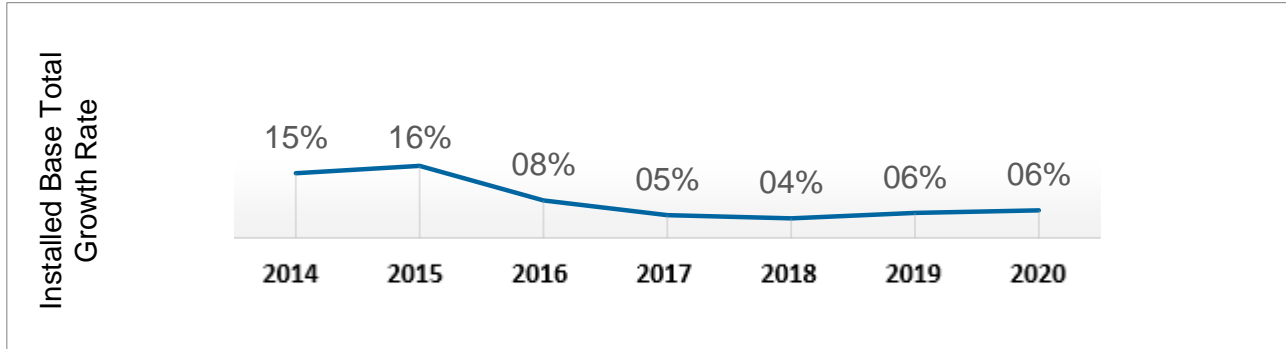
Thaís Caldara Mussi,¹ Tatiana Martins,^{1,2} Rodrigo Gobbo Garcia,³
Renee Zon Filippi,⁴ Gustavo Caserta Lemos,⁵ Ronaldo Hueb Baroni¹

AV	Contrast	Sensitivity	Specificity	PPV	NPV	Accuracy
Reader 1	With	63.0 (54.8-71.3)	77.1 (72.3-81.9)	38.8 (30.0-47.5)	88.0 (83.9-92.1)	73.0 (68.8-77.3)
	Without	63.7 (54.5-72.9)	75.9 (71.2-80.6)	36.5 (28.0-45.0)	88.1 (84.0-92.2)	72.2 (68.0-76.4)
	p-value	0.837	0.551	0.084	0.752	0.599
	N	274	1142	448	968	1416
Reader 2	With	80.7 (73.9-87.6)	57.1 (51.8-62.4)	30.7 (23.4-38.0)	91.3 (87.7-94.9)	60.6 (55.8-65.4)
	Without	74.0 (65.3-82.7)	65.5 (60.1-71.0)	29.9 (22.7-37.2)	89.8 (86.0-93.6)	66.1 (61.4-70.9)
	p-value	0.052	0.004	0.494	0.109	0.024
	n	271	1139	660	750	1410

Custo / reembolso da RMmp no Brasil



Brazil MR Installed Base Forecast



Source: COCIR

RM biparamétrica: o futuro do rastreamento por imagem??

BJU Int 2015; 115: 381–388

BJUI
BJU International

Diagnostic value of biparametric magnetic resonance imaging (MRI) as an adjunct to prostate-specific antigen (PSA)-based detection of prostate cancer in men without prior biopsies

Soroush Rais-Bahrami*, M. Minhaj Siddiqui*, Srinivas Vourganti*, Baris Turkbey¹, Ardeshir R. Rastinehad*, Lambros Stamatakis*, Hong Truong*, Annerleim Walton-Diaz*, Anthony N. Hoang*, Jeffrey W. Nix*, Maria J. Merino², Bradford J. Wood³, Richard M. Simon⁴, Peter L. Choyke¹ and Peter A. Pinto*⁵

*Urologic Oncology Branch, ¹Molecular Imaging Program, ²Laboratory of Pathology, ³Center for Interventional Oncology, and ⁴Biometric Research Branch, National Cancer Institute, National Institutes of Health, Bethesda, MD, USA

lesions (SPL) on B-MRI. B-MRI performed well for the detection of prostate cancer with an area under the curve (AUC) of 0.80 (compared with 0.66 and 0.74 for PSA level and PSAD, respectively). We derived combined PSA and

Combined Biparametric Prostate Magnetic Resonance Imaging and Prostate-specific Antigen in the Detection of Prostate Cancer: A Validation Study in a Biopsy-naive Patient Population



Michele Fascelli, Soroush Rais-Bahrami, Sandeep Sankineni, Anna M. Brown, Arvin K. George, Richard Ho, Thomas Frye, Amichal Kilchevsky, Raju Chelluri, Steven Abboud, M. Minhaj Siddiqui, Maria J. Merino, Bradford J. Wood, Peter L. Choyke, Peter A. Pinto, and Baris Turkbey
UROLOGY 88: 125–134, 2016.

Screen positive lesions on B-MRI had the highest sensitivity (95.5%) and negative predictive value of 71.4% compared with PSA and PSAD. B-MRI significantly improved sensitivity (43.2–72.7%, $P = .0002$) when combined with PSAD. The negative predictive value of PSA increased with B-MRI, achieving 91.7% for B-MRI and PSA for Gleason $\geq 3 + 4$. Overall accuracies of the composite equations were 81.4% (B-MRI and PSA) and 78.0% (B-MRI and PSAD).

Research

Biparametric versus multiparametric MRI in the diagnosis of prostate cancer

Karen Cecilie Duus Thestrup¹, Vibeke Logager¹, Ingerd Baslev², Jakob M Møller¹, Rasmus Hvass Hansen¹ and Henrik S Thomsen¹

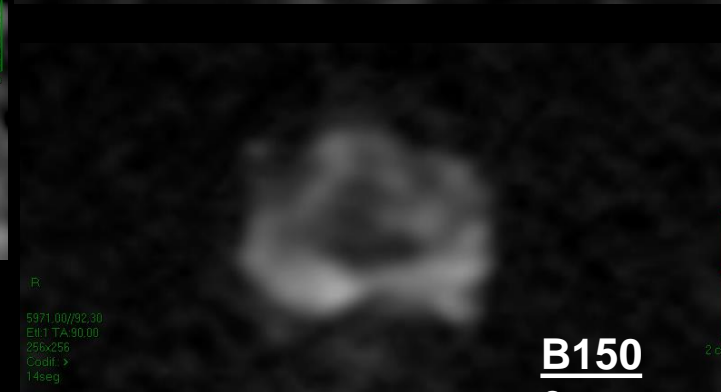
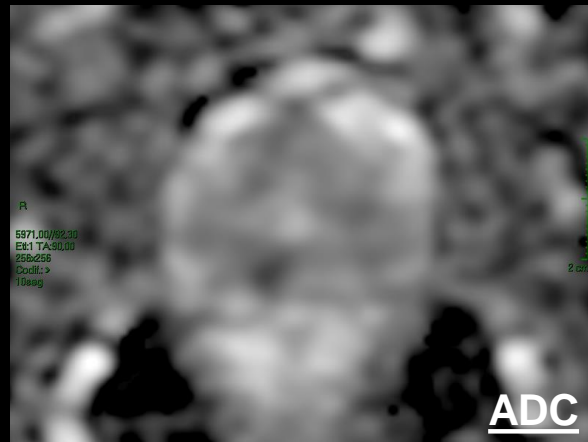
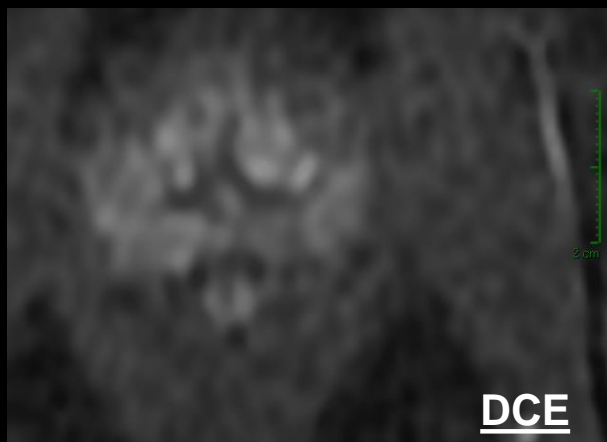
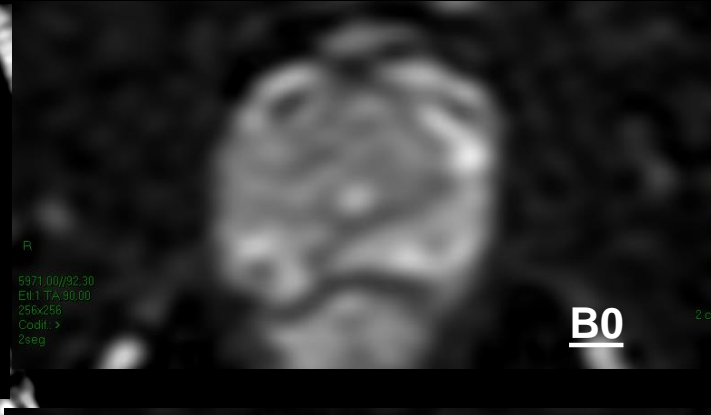
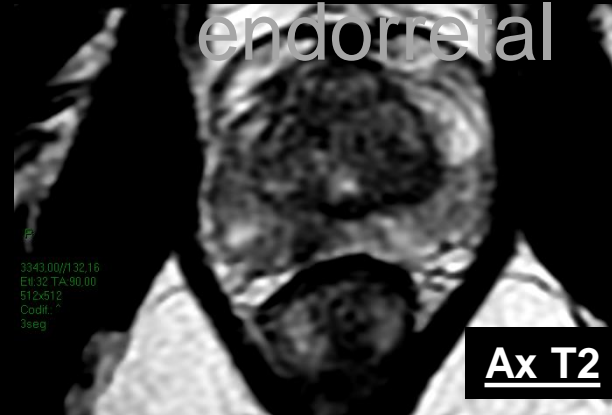
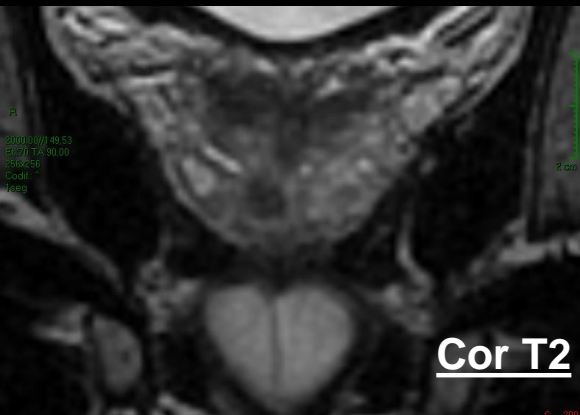
Acta Radiologica Open
5(8) 1–8
© The Foundation Acta Radiologica
2016
Reprints and permissions:
sagepub.co.uk/journalsPermissions.nav
DOI: 10.1177/2058460116663046
arr.sagepub.com



Table 4. The detection rates of Readers 1 and 2.

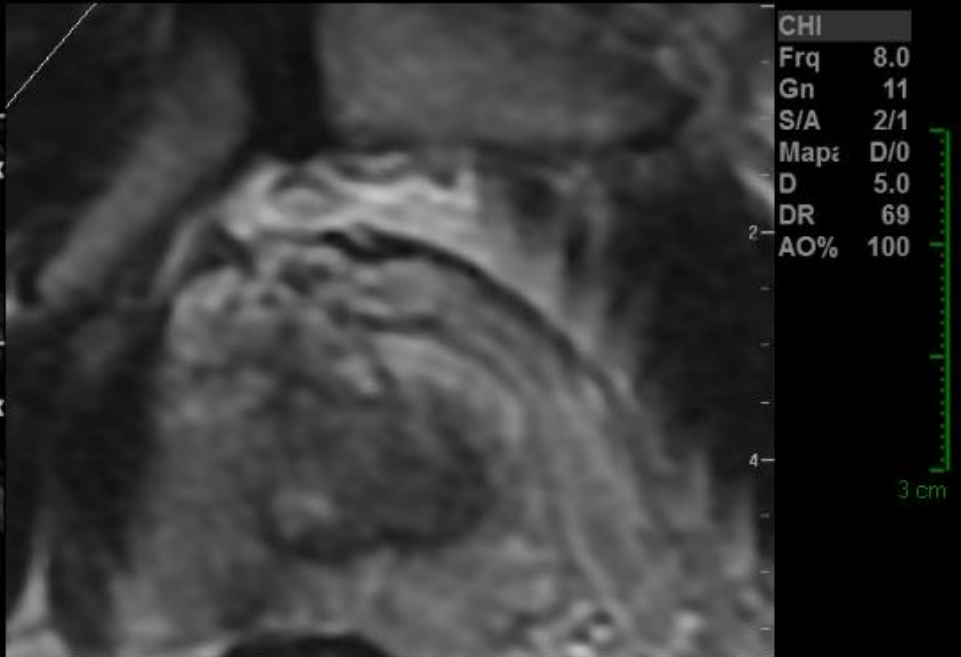
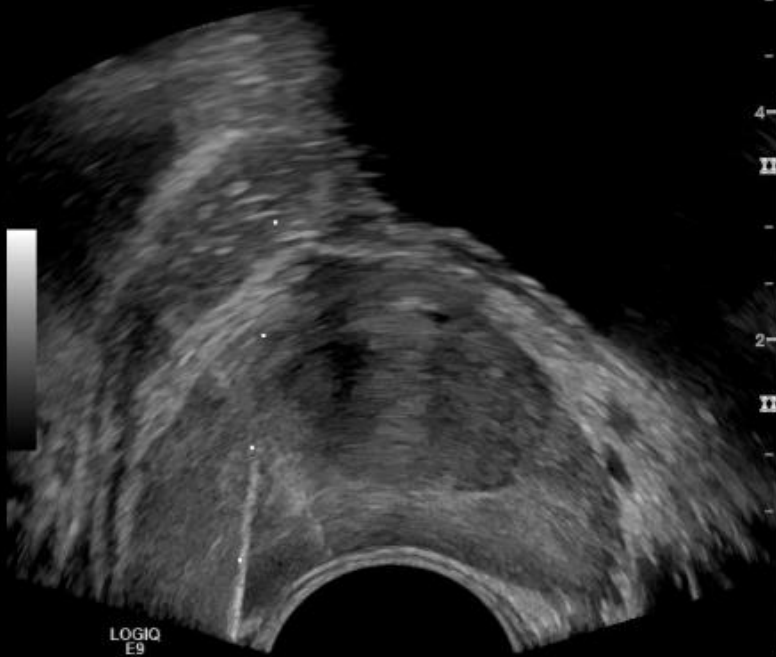
	Reader 1		Reader 2	
	bp-MRI	mp-MRI	bp-MRI	mp-MRI
Sensitivity	0.94	1.0	0.96	0.93
Specificity	0.15	0.04	0.15	0.16
PPV	0.36	0.34	0.36	0.36
NPV	0.83	1.00	0.87	0.81

61 anos, vigilância ativa (GLEASON 6) RMmp em aparelho de 1.5T sem bobina endorreital



12 minutos e 25 segundos exame de R\$350,00

Biópsia com fusão de Imagens



GLEASON 6 → GLEASON 7 (4+3)

Cost-effectiveness of MR Imaging–guided Strategies for Detection of Prostate Cancer in Biopsy-Naive Men¹

Shivani Pahwa, MD
Nicholas K. Schiltz, PhD
Lee E. Ponsky, MD
Ziang Lu, BA
Mark A. Griswold, PhD
Vikas Gulani, MD, PhD

Purpose:

To evaluate the cost-effectiveness of multiparametric diagnostic magnetic resonance (MR) imaging examination followed by MR imaging–guided biopsy strategies in the detection of prostate cancer in biopsy-naive men presenting with clinical suspicion of cancer for the first time.

Results:

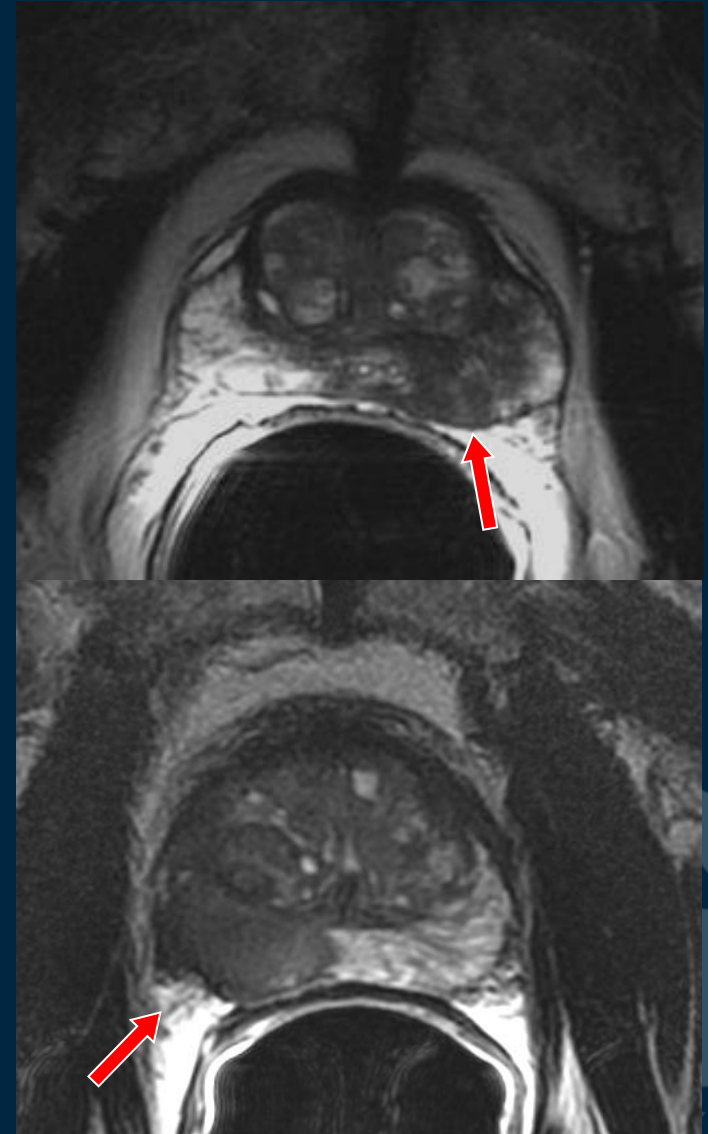
Noncontrast MR imaging followed by cognitively guided MR biopsy (no standard biopsy if MR imaging findings were negative) was the most cost-effective approach, yielding an additional NHB of 0.198 QALY compared with the standard biopsy approach. Noncontrast MR imaging followed by in-gantry MR imaging–guided biopsy (no standard biopsy if MR imaging findings were negative) led to the highest NHB gain of 0.251 additional QALY compared with the standard biopsy strategy. All MR imaging strategies were cost-effective in 94.05% of Monte Carlo simulations. Analysis by age groups yielded similar results.

¹From the Departments of Radiology (S.P., M.A.G., V.G.) and Urology (L.E.P.), University Hospitals Case Medical Center, 11100 Euclid Ave, Bolwell B120, Cleveland, OH 44106-0500; Department of Epidemiology and Biostatistics (N.K.S.) and Department of Biomedical Engineering (M.A.G., V.G.), Case Western Reserve University, Cleveland, Ohio; and Case Western Reserve University School of Medicine, Cleveland, Ohio (Z.L.). Received September 18, 2016; revision requested November 15; revision received January 22, 2017; accepted February 7; final version accepted February 24. Address correspondence to V.G. (e-mail: vikas.gulani@case.edu).



RM no estadiamento local

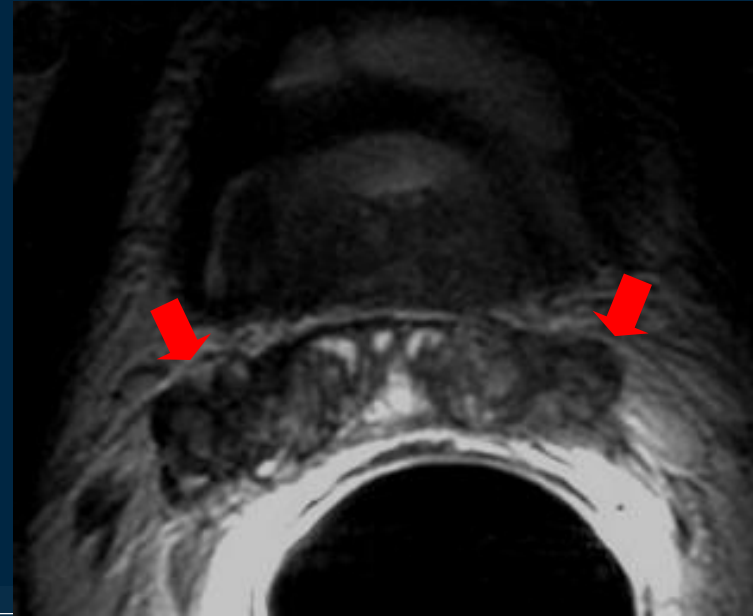
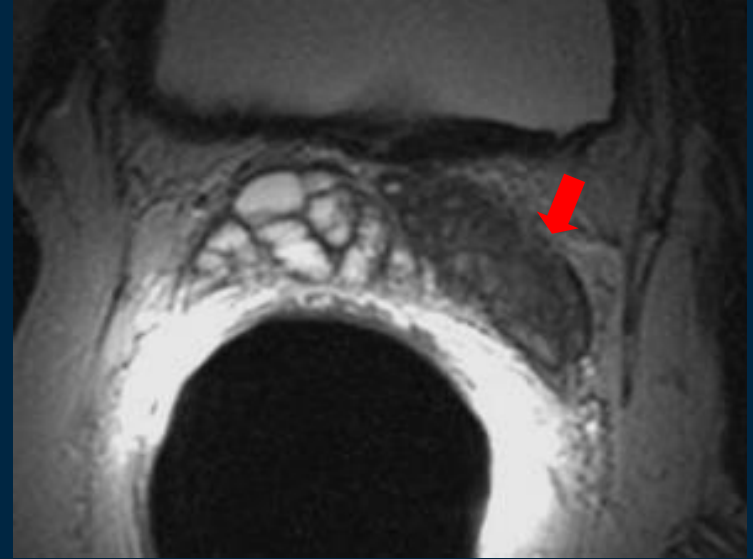
- Sinais de extensão extraprostática





RM no estadiamento local

- Invasão de vesículas seminais

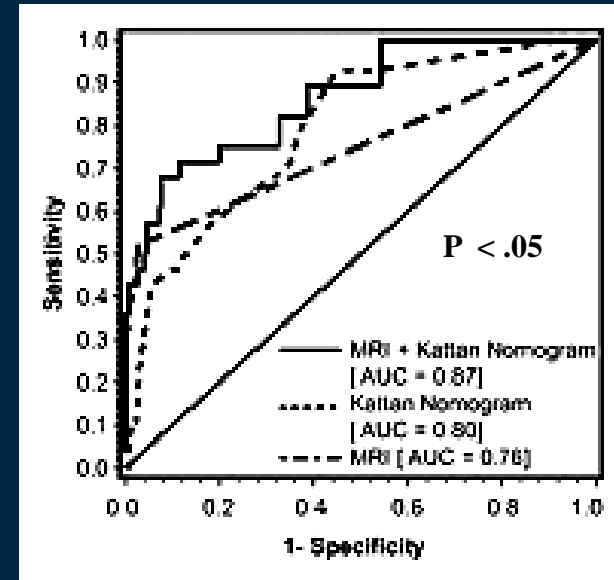
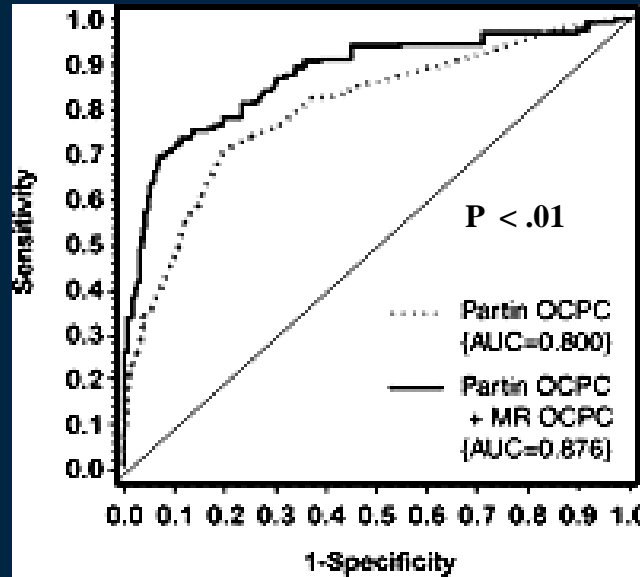
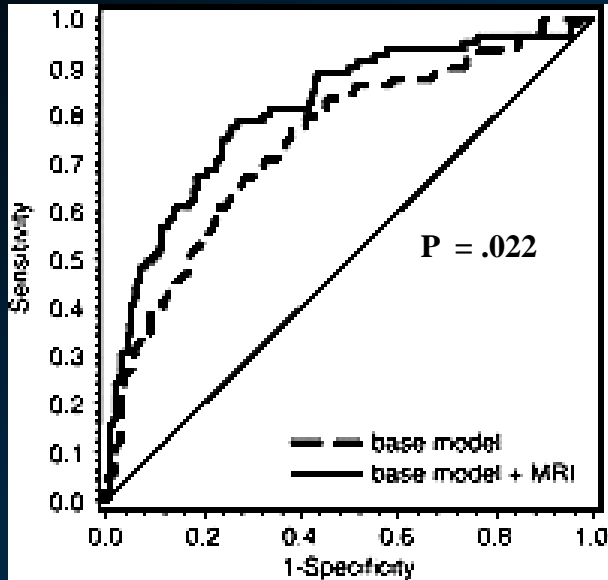




Nomogramas: valor incremental da

RM

Liang Wang, MD, Michael W. Kattan, PhD, Peter T. Scardino, MD and Hedvig Hricak, MD, PhD



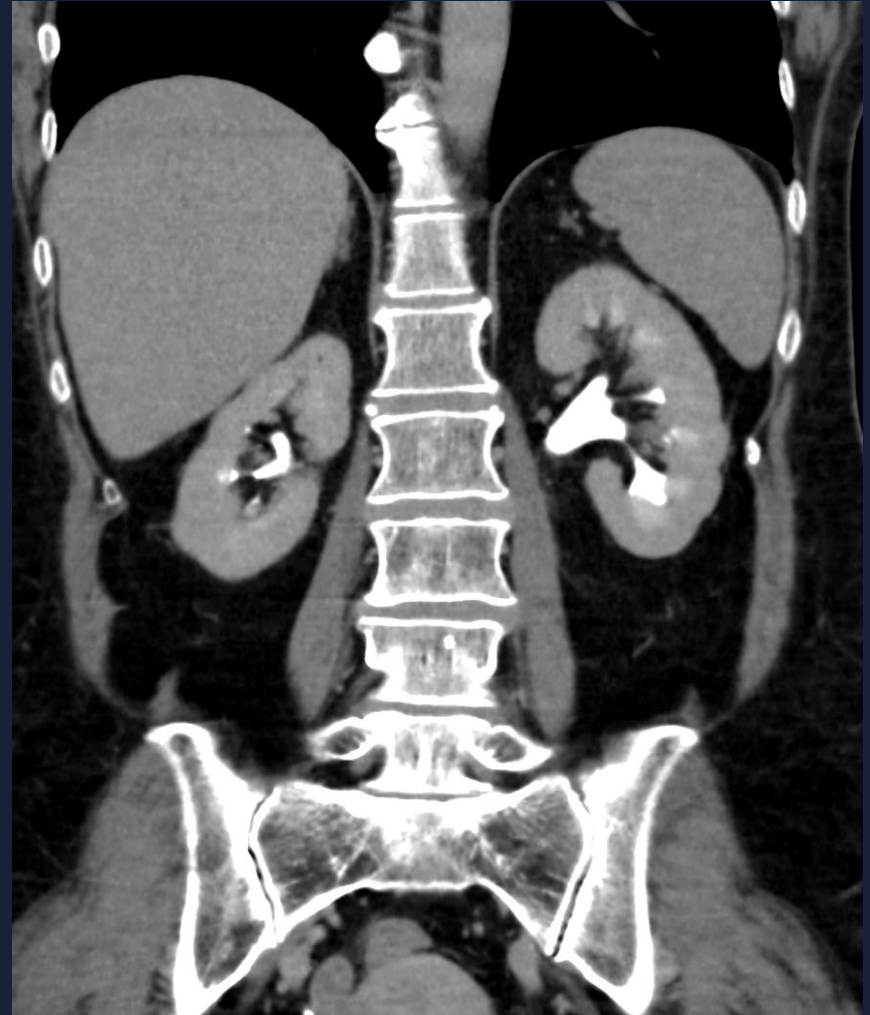
- Predição de extensão extracapsular
- 344 pacientes
- RM: melhor variável na análise univariada e multivariada

- Predição de doença órgão confinada
- 229 pacientes
- RM ainda melhor para pacientes de risco intermediário e alto

- Predição de invasão de VVSS
- 573 pacientes
- RM: maior curva ROC dentre todas as variáveis isoladas

Estadiamento do Ca prostático

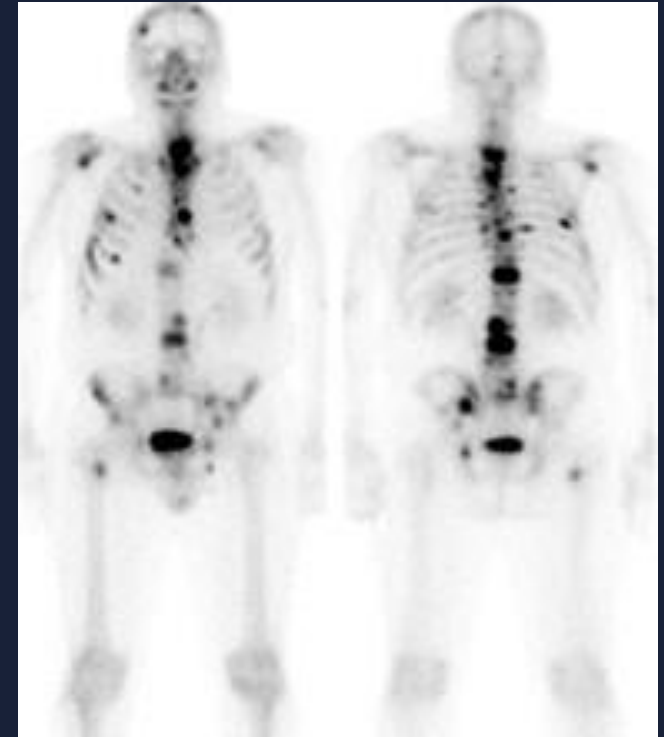
- TC / RM abdome total
 - < 1% de positividade em PSA < 20



Estadiamento do Ca prostático

TC / RM abdome tota < 1% de positividade em PSA < 20

- Cintilografia óssea:



Faixa de PSA (ng/ml)	< 10	10 a 19,9	20 a 49,9	50 a 99,9	> 100
% de positividade da cintilografia	2,3	5,3	16,2	39,2	73,4

Estadiamento do Ca prostático

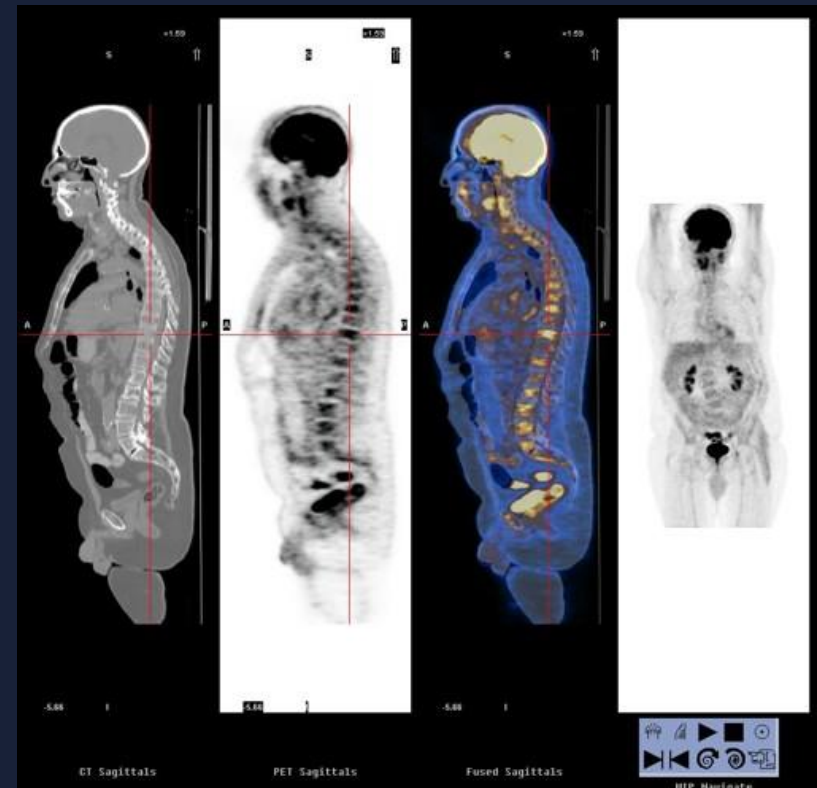
TC / RM abdome total

< 1% de positividade em PSA < 20

Cintilografia óssea

- **PET-CT:**

- Captação baixa - metabolismo pouco aumentado em tumores de crescimento lento (sens. < 5%)
- Menor sensibilidade que a cintilografia óssea



Liu, IJ et al. Urology. 2001;57:108-11.



MEDICINA NUCLEAR EM CÂNCER DE PROSTATA

- Novos radiofármacos
 - *Diagnóstico:*
 - ^{18}F -Fluoreto
 - ^{68}Ga -PSMA





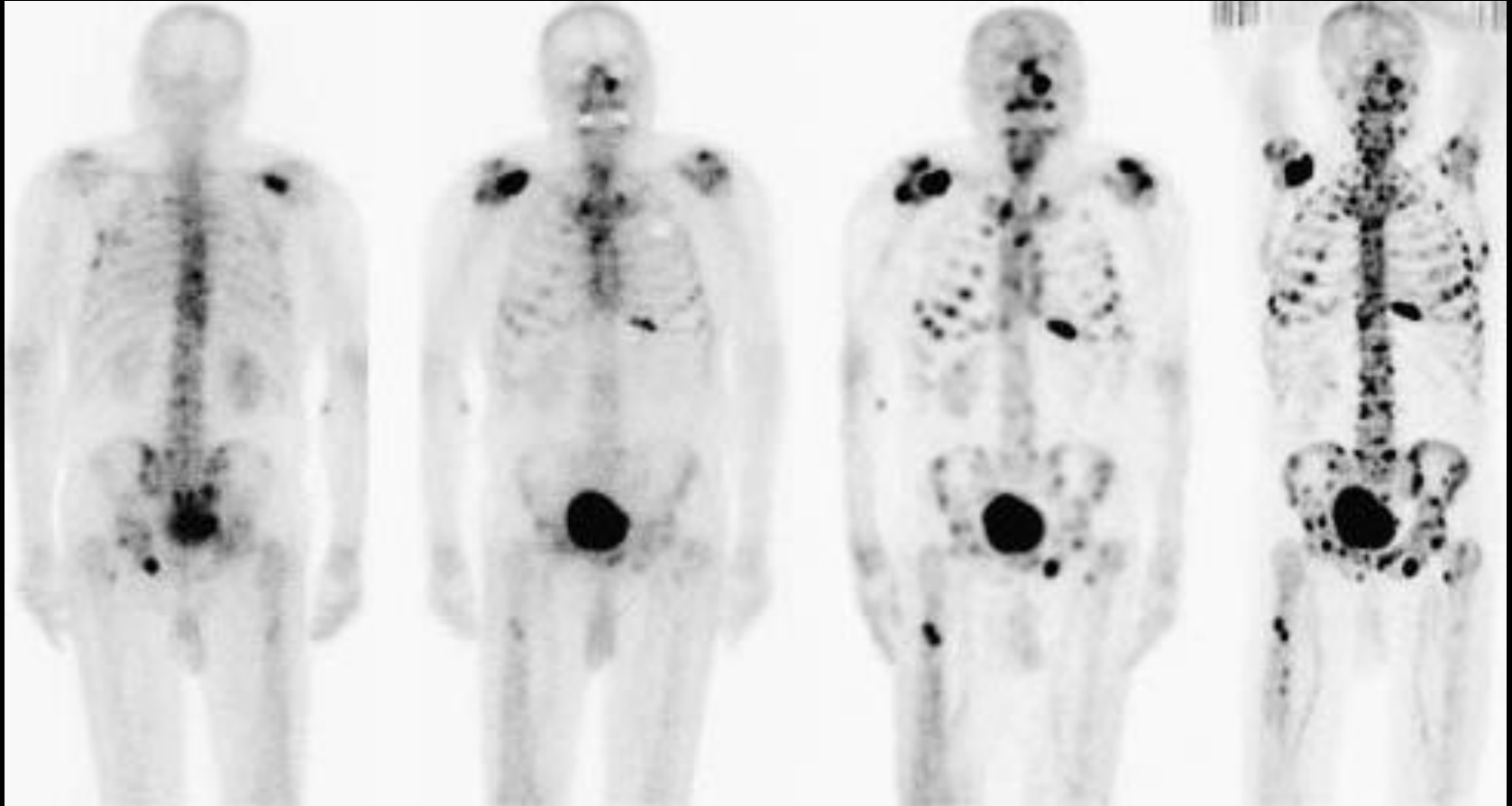
PET/CT com ^{18}F -Fluoreto

Assessment of Skeletal Metastatic Spread by Planar $^{99\text{m}}\text{Tc}$ -MDP BS, Planar and SPECT BS, ^{18}F -Fluoride PET, and ^{18}F -Fluoride PET/CT: Patient-Based Analysis in 44 Patients with High-Risk Prostate Cancer

Modality	Final diagnosis						Interpretation*			
	Spread of metastases (n = 23)			No metastases (n = 11)			Sensitivity (%)	Specificity (%)	PPV (%)	NPV (%)
	M	E	B/N	M	E	B/N				
Planar BS	8	5	10	1	8	12	57 (35)	57 (95)	59 (89)	55 (44)
Planar + SPECT†	9	9	5	3	4	14	78 (39)	67 (86)	72 (75)	74 (31)
^{18}F -Fluoride PET	11	12	0	1	7	13	100 (48)	62 (95)	74 (92)	100 (63)
^{18}F -Fluoride PET/CT	20	3	0	0	0	21	100 (87)	100 (100)	100 (100)	100 (87)

Even-Sapir et al.. J Nucl Med 2006;47:287-297.

PET/CT com ^{18}F -Fluoreto



CINTILOGRAFIA
ÓSSEA

CINTILOGRAFIA
ÓSSEA (SPECT)

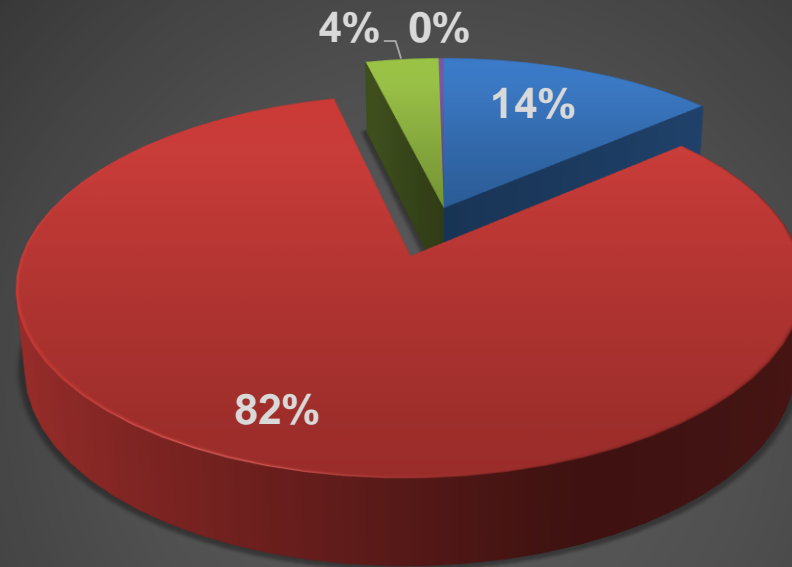
PET/CT com ^{18}F -
Fluoreto

PSMA – Prostate Specific Membrane Antigen

- PSMA é uma glicoproteína transmembrana com expressão elevada em adenocarcinomas de próstata, notadamente nos pouco diferenciados, metastáticos e hormônio resistentes.
- É expressada também em tecidos normais como glândulas salivares, lacrimais, delgado proximal, túbulos renais, na subpopulação de células neuroendócrinas de criptas cólicas e no endotélio de neovasos de várias neoplasias.

Experiência HIAE com PET-CT PSMA: 1800 casos

INDICAÇÕES PARA PET-CT PSMA



- DI Rastreamento / estadiamento primário
- RE Recorrência
- CS Seguimento
- OI Outros

PET imaging with a [⁶⁸Ga]gallium-labelled PSMA ligand for the diagnosis of prostate cancer: biodistribution in humans and first evaluation of tumour lesions

A. Afshar-Oromieh • A. Malcher • M. Eder • M. Eisenhut •
H. G. Linhart • B. A. Hadaschik • T. Holland-Letz •
F. L. Giesel • C. Kratochwil • S. Haufe • U. Haberkorn •
C. M. Zechmann

Results The PET/CT images showed intense tracer uptake in both kidneys and salivary glands. Moderate uptake was seen in lacrimal glands, liver, spleen and in small and large bowel. Quantitative assessment revealed excellent contrast between tumour lesions and most normal tissues. Of 37 patients, 31 (83.8 %) showed at least one lesion suspicious for cancer at a detection rate of 60 % at PSA <2.2 ng/ml and 100 % at PSA >2.2 ng/ml. Median tumour to background ratios were 18.8



PET/CT com PSMA-⁶⁸Ga

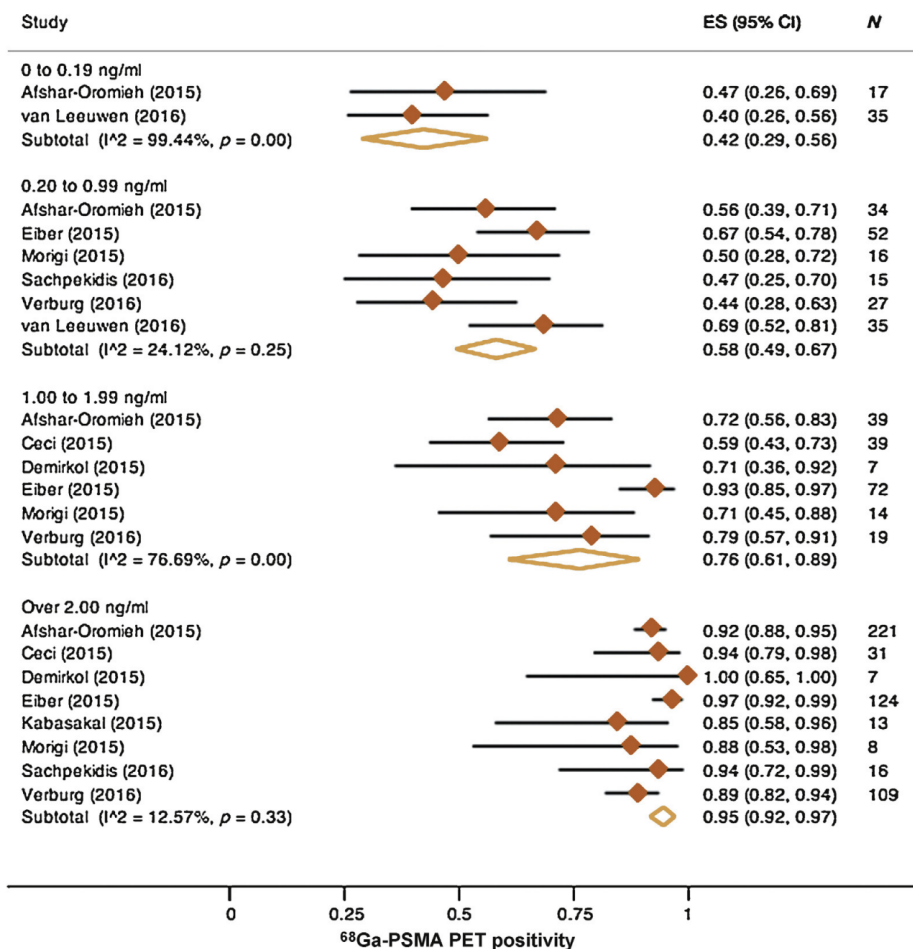
RESULTADOS (recidiva bioquímica)

- Maior série, 319 indivíduos incluídos:
- Análise baseada em todas as lesões identificadas na investigação:
- S=76,6%, E=100% VPP=91,4% e VPN=100%

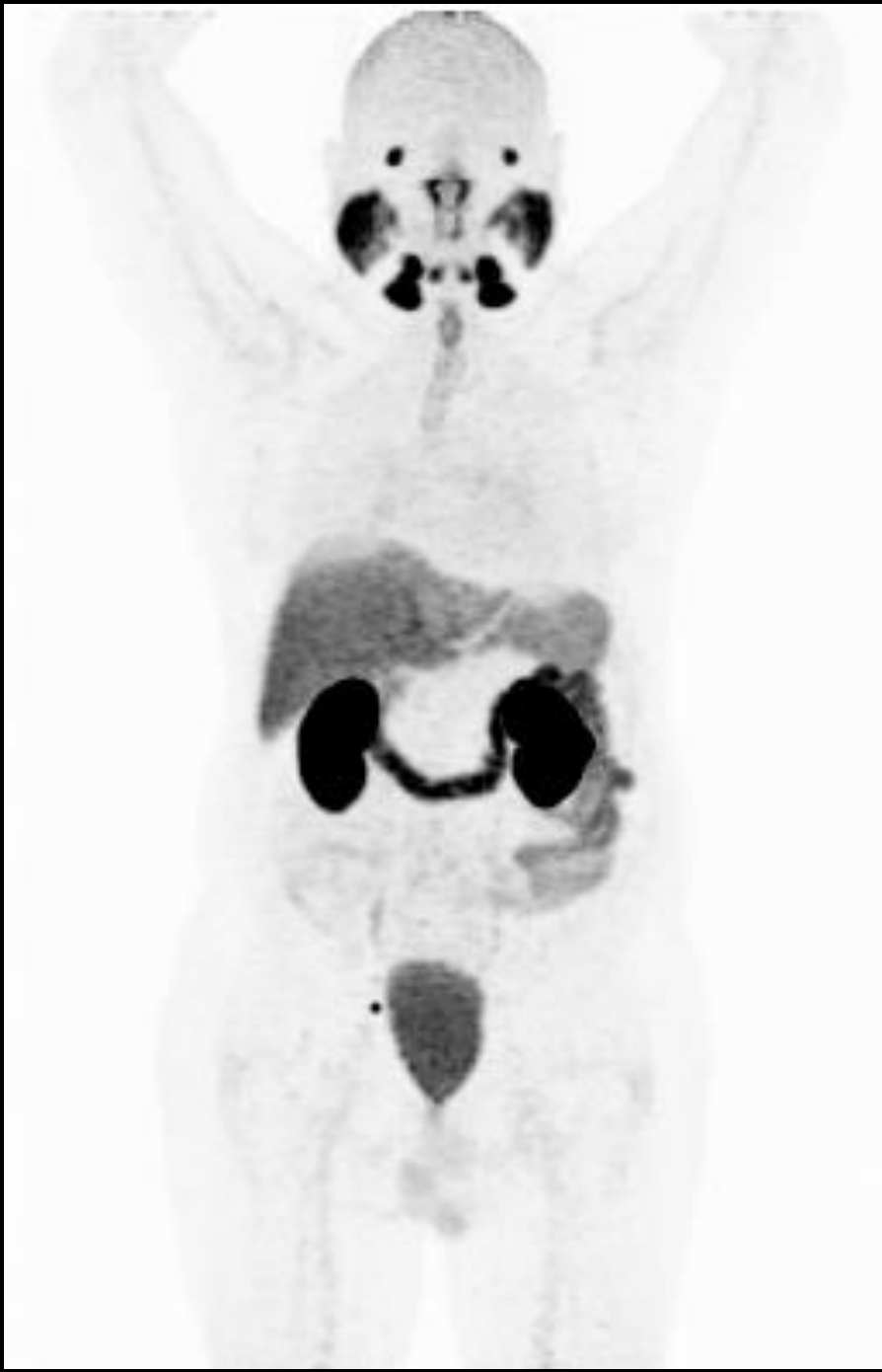Ashar-Oromieh A et al. Eur J Nucl Med Imaging (2015)42:197-209

Sensitivity, Specificity, and Predictors of Positive ⁶⁸Ga-Prostate-specific Membrane Antigen Positron Emission Tomography in Advanced Prostate Cancer: A Systematic Review and Meta-analysis

Marlon Perera^a, Nathan Papa^a, Daniel Christidis^a, David Wetherell^a, Michael S Hofman^b, Declan G Murphy^{c,e}, Damien Bolton^{a,d}, Nathan Lawrentschuk^{a,c,d,*}



Eur Urol. 2016 Dec;70(6):926-937



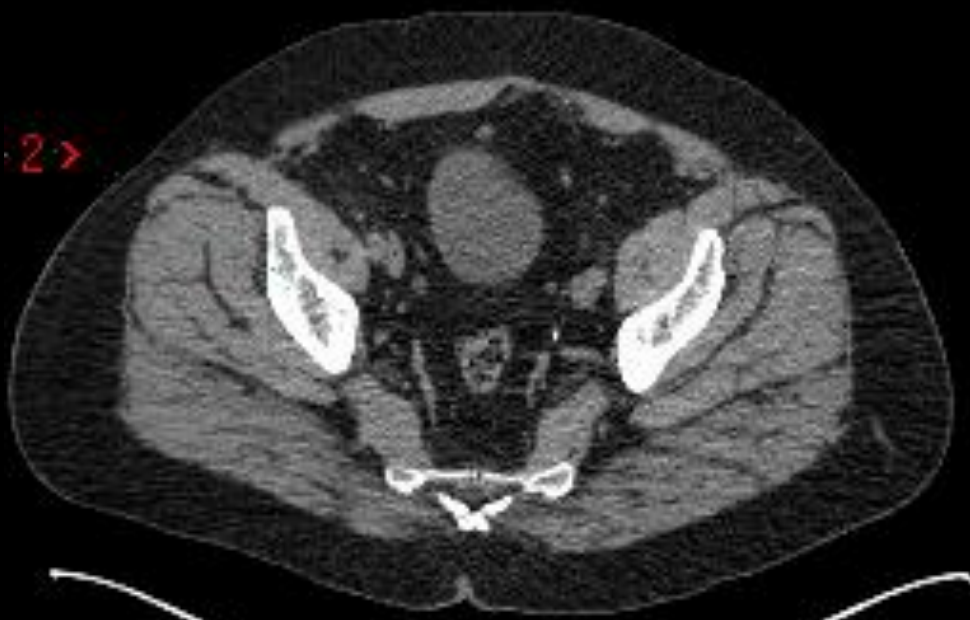PET/CT

03/02/201

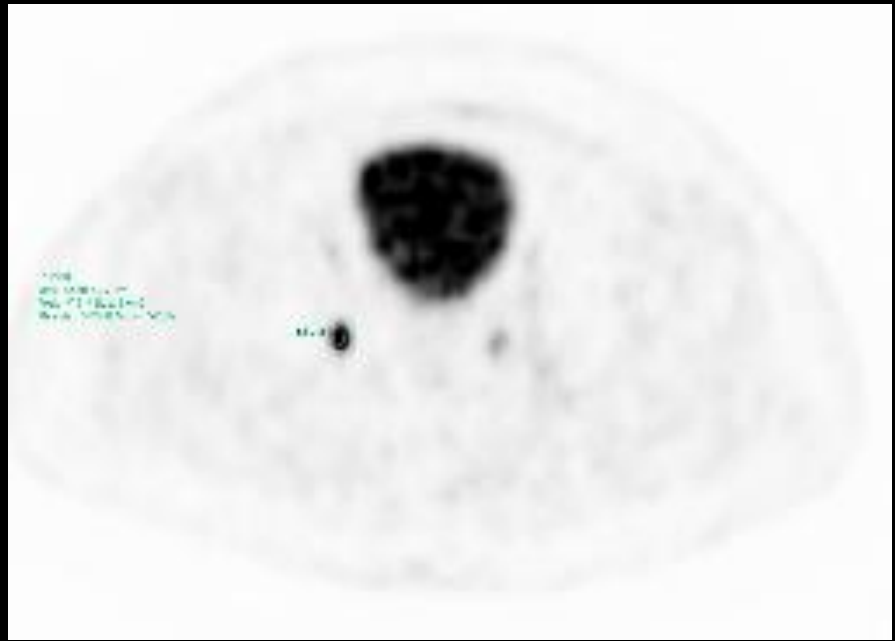
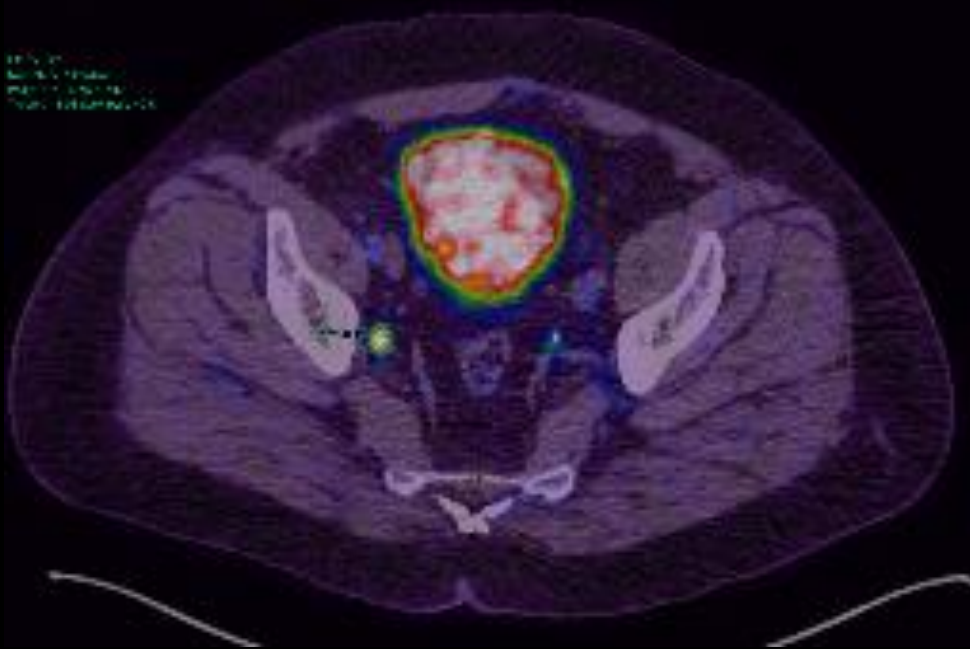
6

71 a, Ca de próstata 2006, prostatectomia com Gleason 8, nunca fez bloqueio androgênico, radioterapia 2011, aumento de PSA (0,5 atual).

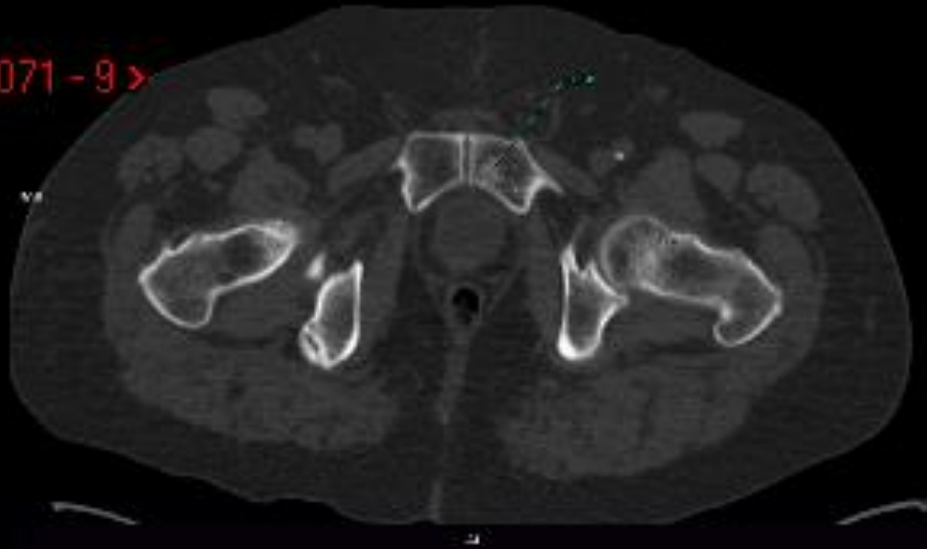2 >



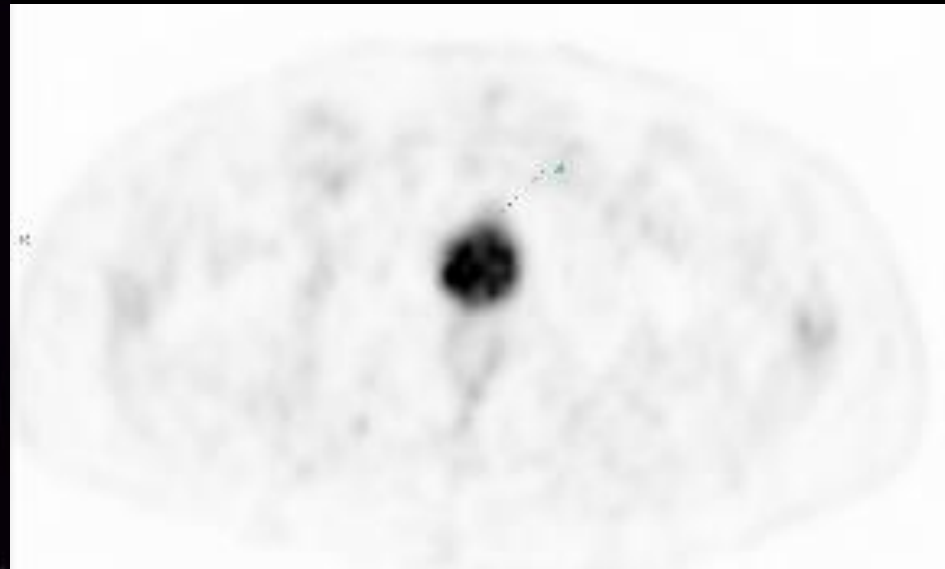
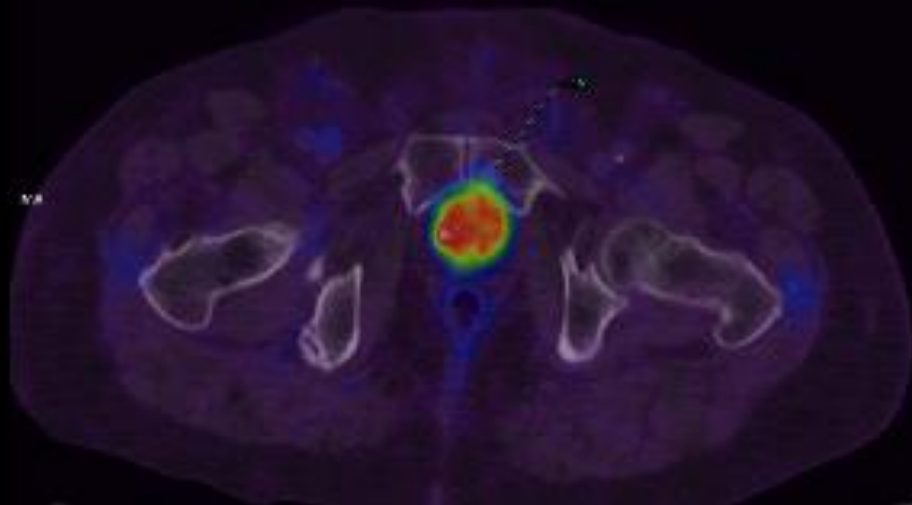
PET/CT
03/02/2016



1071-9 >



PET/CT
03/02/2016



Biopsia

02/02/2016

Microscopia e Conclusões Diagnósticas

A, B e D) Biópsia de lesão de osso pube à esquerda:
Tecido ósseo com áreas de esclerose e remodelação
Negativo para neoplasia nesta amostra

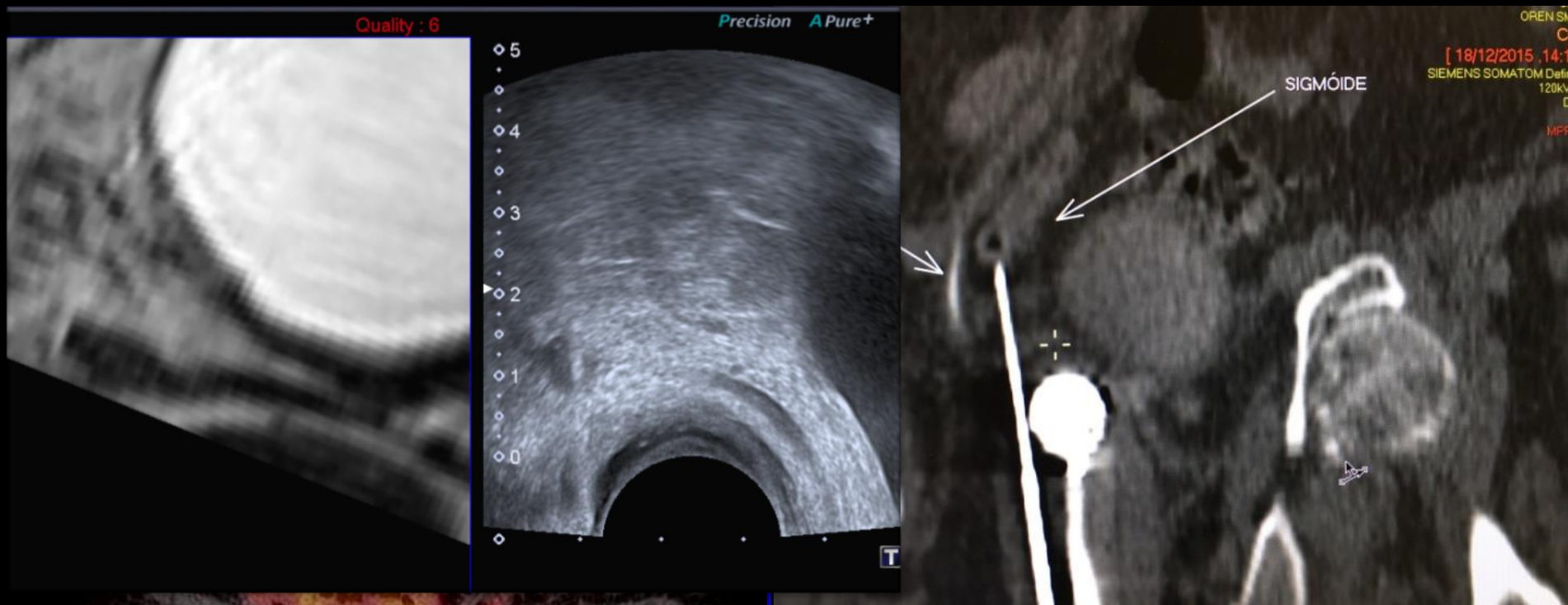
C) Linfonodo obturatório à direita:
Adenocarcinoma metastático, ver nota
Amostras filiformes de tecido fibroadiposo infiltrada por neoplasia epitelial constituída
por ácinos de tamanhos variados com escasso estroma

§

Diagnóstico

O perfil imuno-histoquímico associado aos achados morfológicos é de Adenocarcinoma metastático de sítio primário provável em próstata.

PET/CT e PET/RM com PSMA-⁶⁸Ga



Microscopia e Conclusões Diagnósticas

Biópsia de região pélvica (ducto deferente à direita):

Adenocarcinoma infiltrando parede de ducto deferente e tecido adiposo adjacente
Neoplasia epitelial infiltrativa em arranjo sólido esboçando ácinos focalmente
Infiltração perineural presente

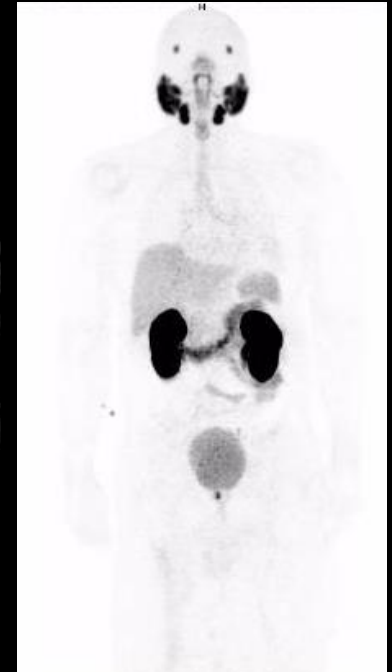
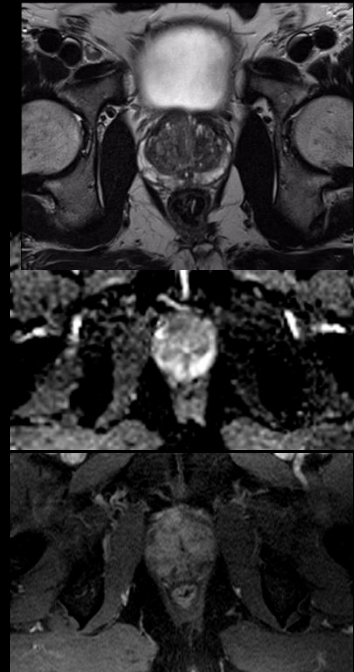
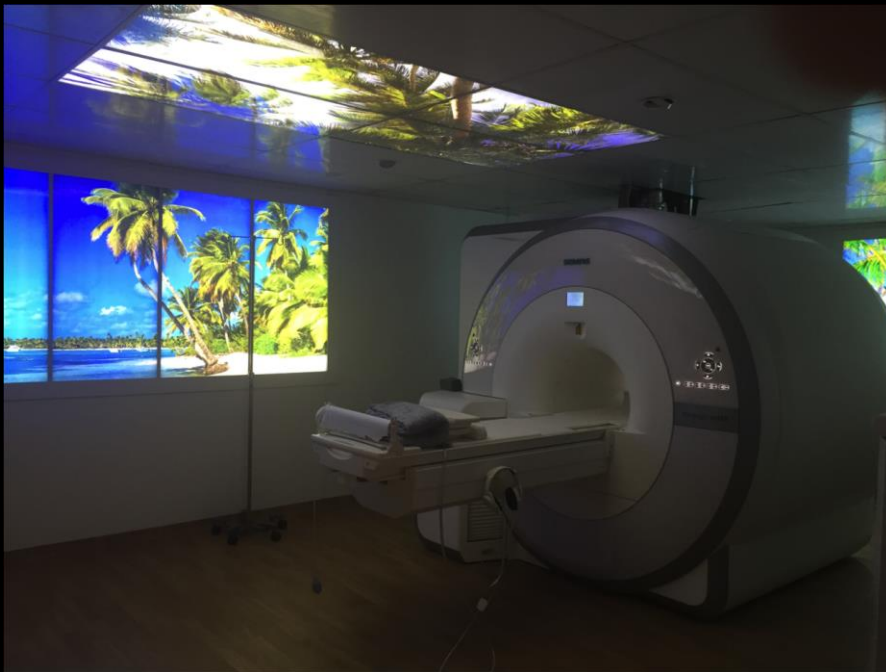Nota: Aspectos histológicos consistentes com sítio primário em próstata. Em andamento exame imuno-histoquímico para confirmação de sítio primário que será emitido em relatório complementar.

PET/MRI: a novel hybrid imaging technique. Major clinical indications and preliminary experience in Brazil

PET/RM: um novo método de imagem híbrida.

Principais indicações clínicas e experiência preliminar no Brasil

Taise Vitor¹, Karine Minaif Martins¹, Tudor Mihai Ionescu¹, Marcelo Livorsi da Cunha¹, Ronaldo Hueb Baroni¹,
Marcio Ricardo Taveira Garcia¹, Jairo Wagner¹, Guilherme de Carvalho Campos Neto¹,
Solange Amorim Nogueira¹, Elaine Gonçalves Guerra¹, Edson Amaro Junior¹



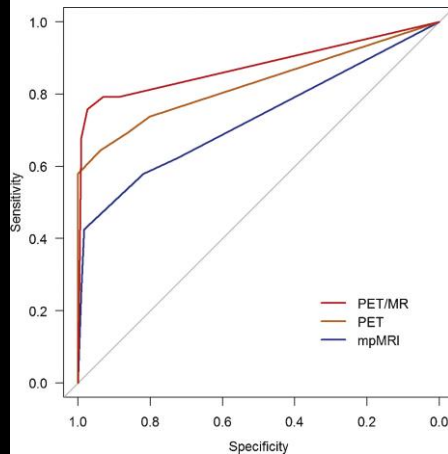
Prostate Cancer

Simultaneous ^{68}Ga -PSMA HBED-CC PET/MRI Improves the Localization of Primary Prostate Cancer

Matthias Eiber^{a,*,\dagger}, Gregor Weirich^{b,\dagger}, Konstantin Holzapfel^c, Michael Souvatzoglou^{a,d}, Bernhard Haller^e, Isabel Rauscher^a, Ambros J. Beer^{a,d}, Hans-Jürgen Wester^f, Juergen Gschwend^g, Markus Schwaiger^{a,\dagger}, Tobias Maurer^{g,\dagger}

^aDepartment of Nuclear Medicine, Technische Universität München, Klinikum rechts der Isar, Munich, Germany; ^bDepartment of Pathology, Technische Universität München, Klinikum rechts der Isar, Munich, Germany; ^cInstitute of Radiology, Technische Universität München, Klinikum rechts der Isar, Munich, Germany; ^dDepartment of Nuclear Medicine, University Hospital Ulm, Ulm, Germany; ^eInstitute of Medical Statistics and Epidemiology, Technische Universität München, Klinikum rechts der Isar, Munich, Germany; ^fPharmaceutical Radiochemistry, Technische Universität München, Garching, Germany; ^gDepartment of Urology, Technische Universität München, Klinikum rechts der Isar, Munich, Germany

Article info



Abstract

Background: Ligands of the prostate-specific membrane antigen (PSMA) show promising results in positron emission tomography (PET) imaging of prostate cancer (PCa). **Objective:** To compare the diagnostic performance of simultaneous gallium 68 (^{68}Ga)-PSMA HBED-CC PET/magnetic resonance imaging (MRI) for localization of primary PCa with multiparametric magnetic resonance imaging (mpMRI) and PET alone. **Design, setting, and participants:** We performed ^{68}Ga -PSMA HBED-CC PET/MRI in 66 men with biopsy-proven PCa. **Intervention:** PET, mpMRI, and combined ^{68}Ga -PSMA HBED-CC PET/MRI were independently evaluated using Prostate Imaging Reporting and Data System criteria or a 5-point Likert scale. **Outcome measurements and statistical analysis:** The prostate was divided into sextants for histopathology and coregistered with imaging. Diagnostic performance for localization of malignancy was calculated based on receiver operating characteristics analysis for each modality. Regional quantitative PET tracer uptake was recorded; uptake ratio was defined as the ratio of malignant to nonmalignant prostate tissue. **Results and limitations:** A total of 53 of 66 patients were eligible for analysis. mpMRI, PET, and PET/MRI detected cancer in 66% (35 of 53), 92% (49 of 53), and 98% (52 of 53) of the patients, respectively. Overall, 202 of 318 sextants (63.5%) contained cancer at pathologic examination. Simultaneous PET/MRI statistically outperformed mpMRI (area under the curve [AUC]: 0.88 vs 0.73; $p < 0.001$) and PET imaging (AUC: 0.88 vs 0.83;

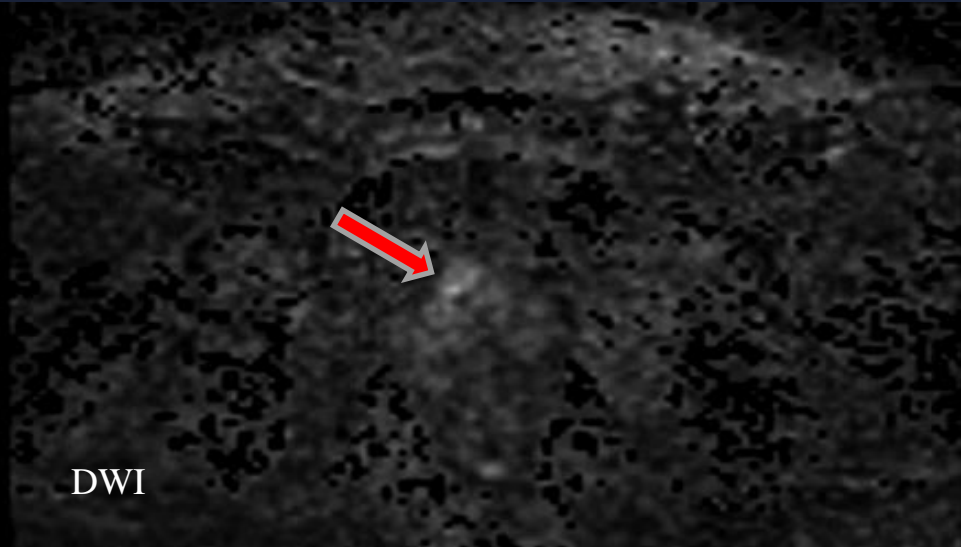
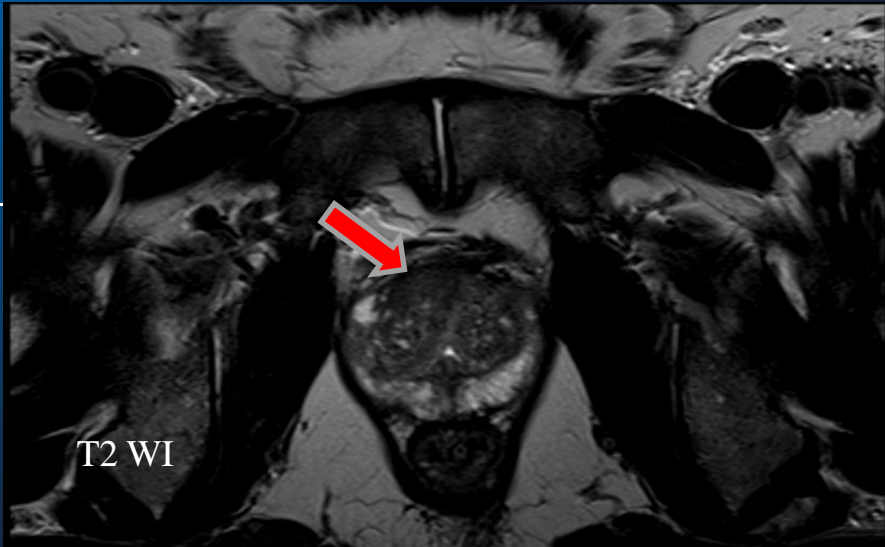


ALBERT EINSTEIN
HOSPITAL ISRAELITA

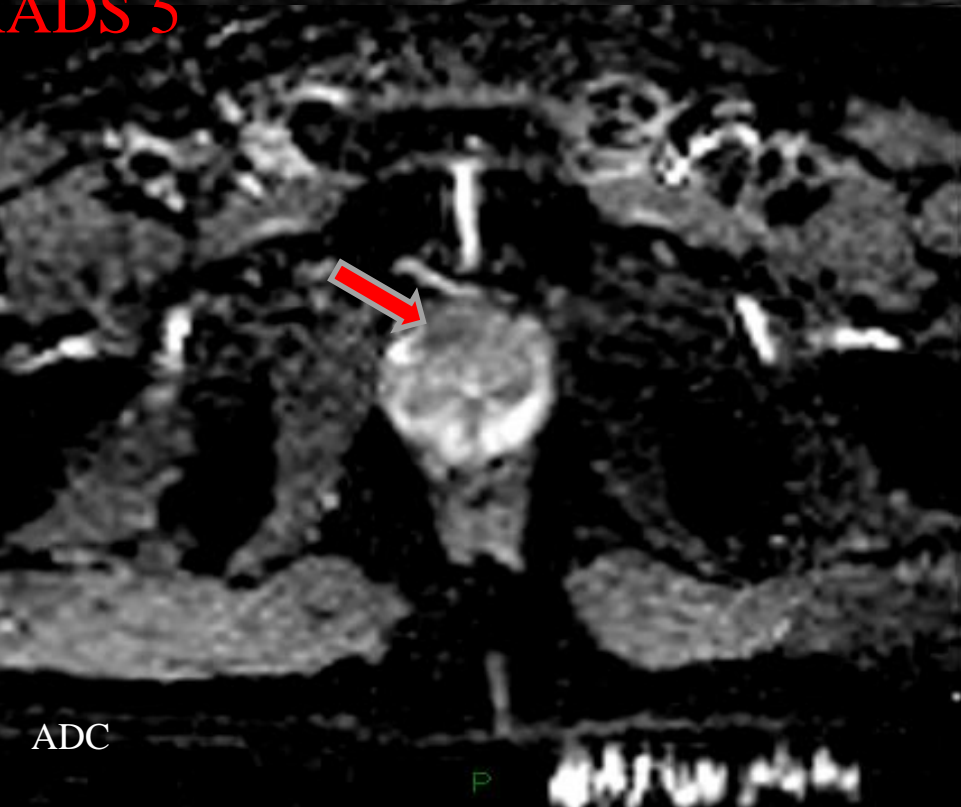
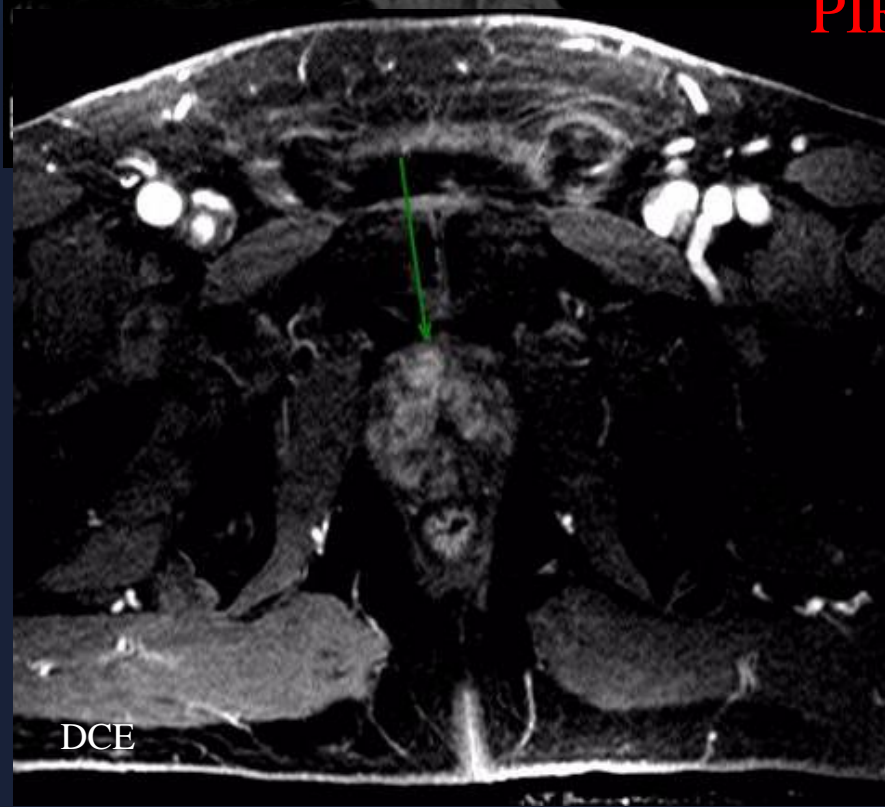
DIAGNÓSTICO POR IMAGEM

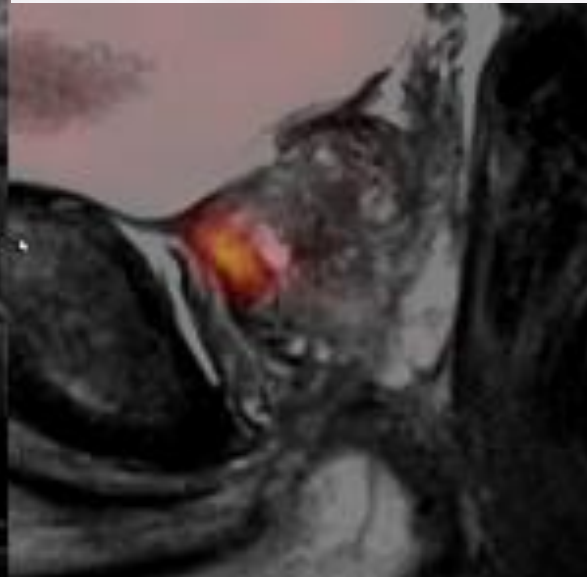
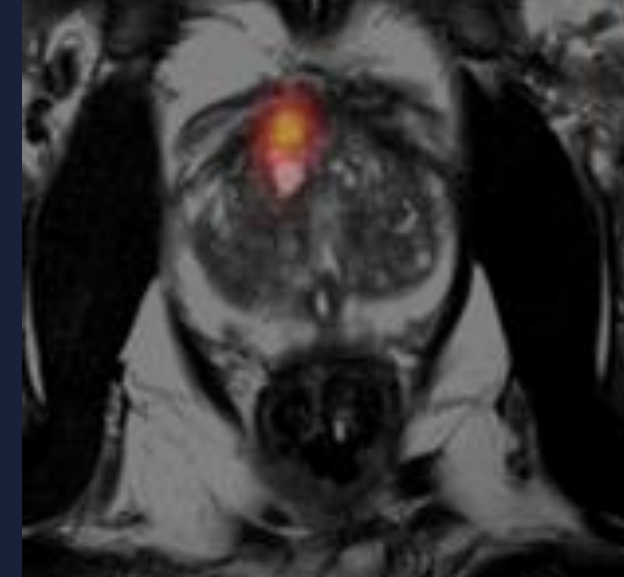
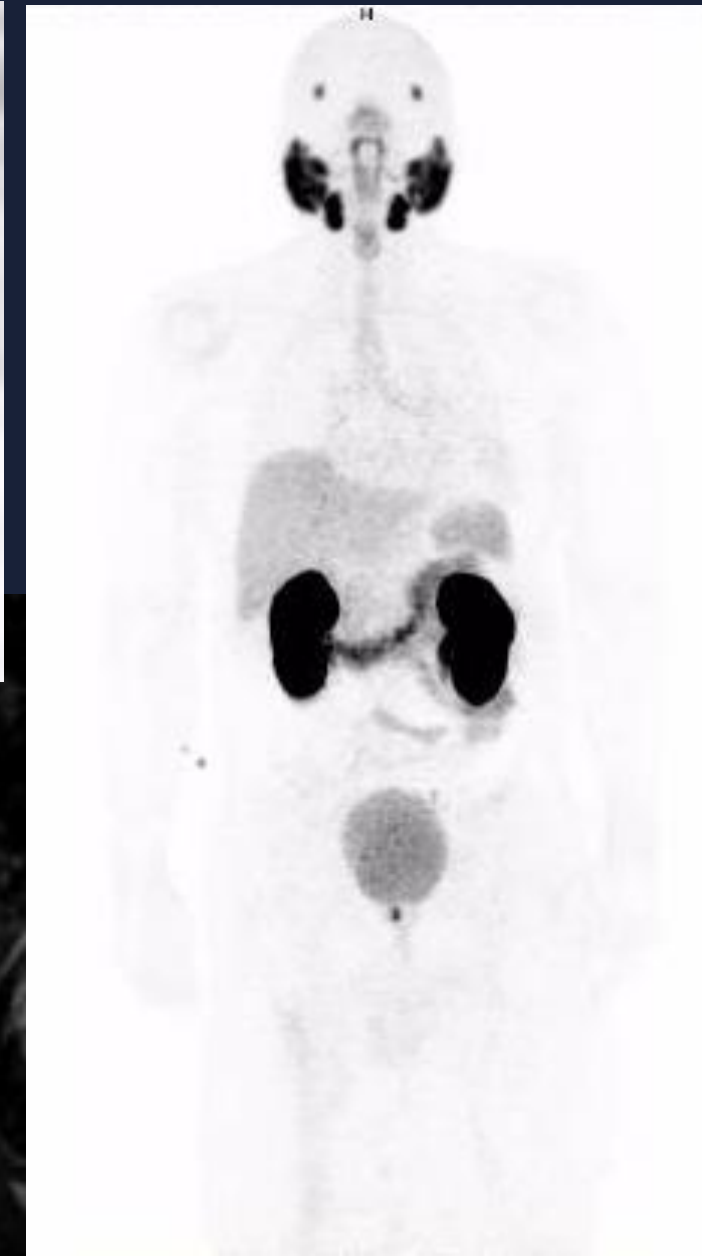
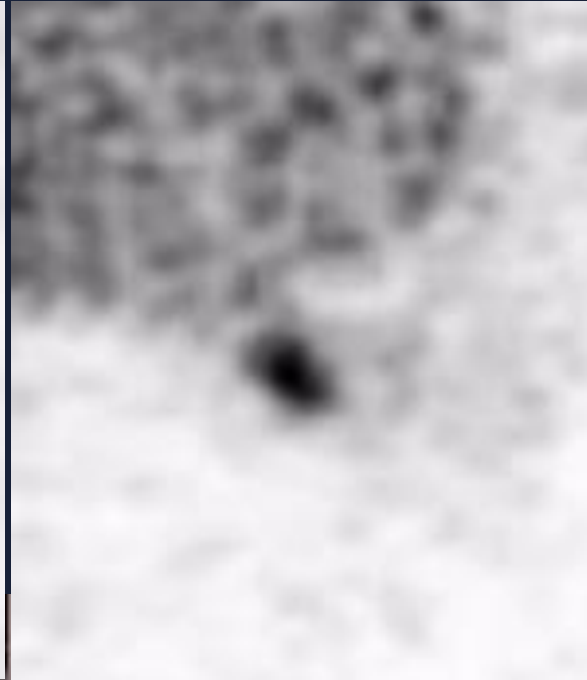
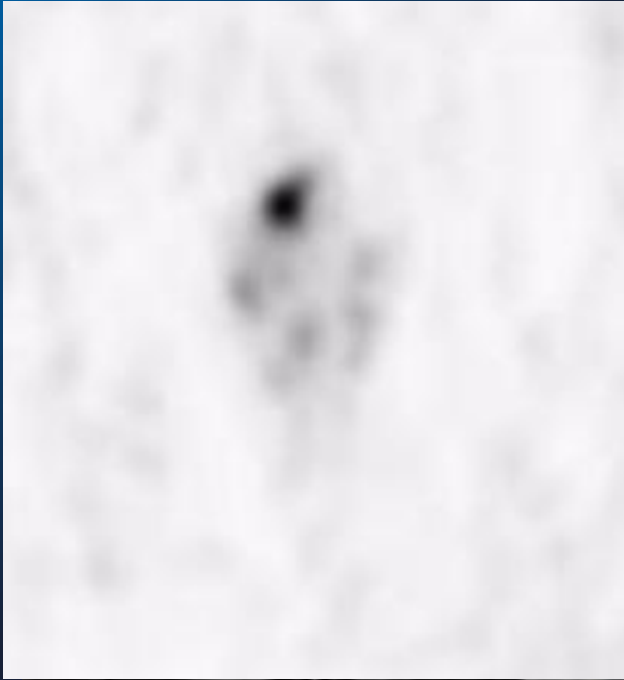


- 63 anos
 - PSA - 12 ng/ml
 - RMmp nos EUA suspeita para Ca (sic)
 - Biópsia há 2 meses nos EUA (URONAV) pelo urologista - negativa
- Discussão do caso radiologista + oncologista: PET-RMmp com PSMA.



PIRADS 5



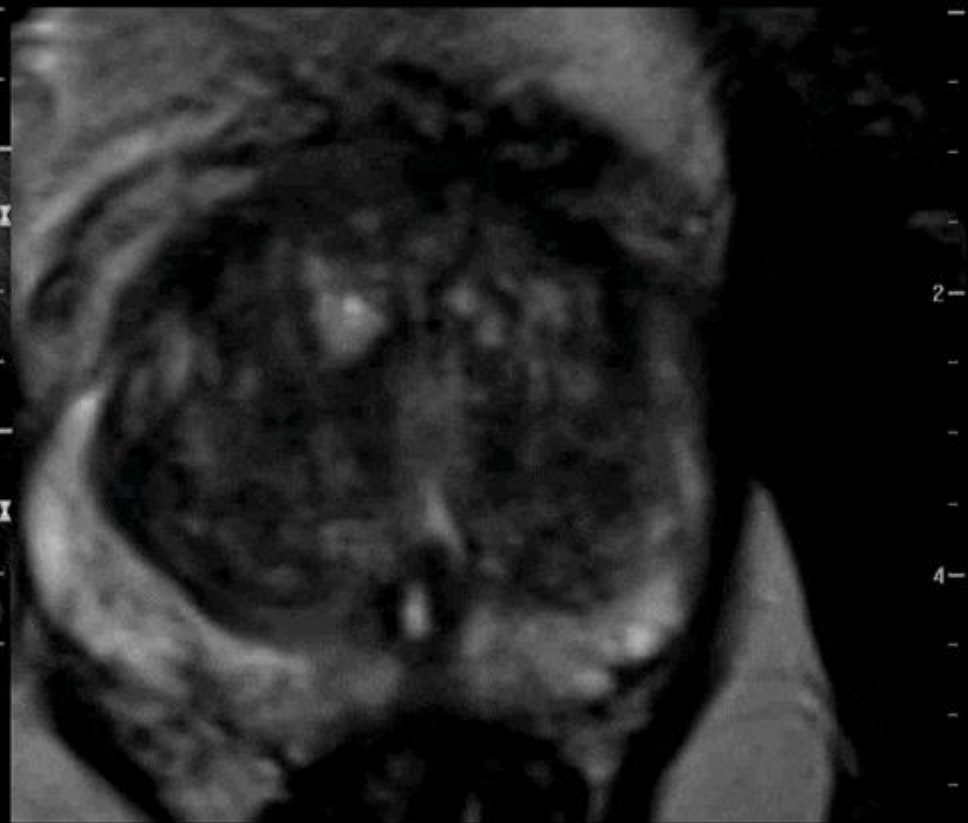
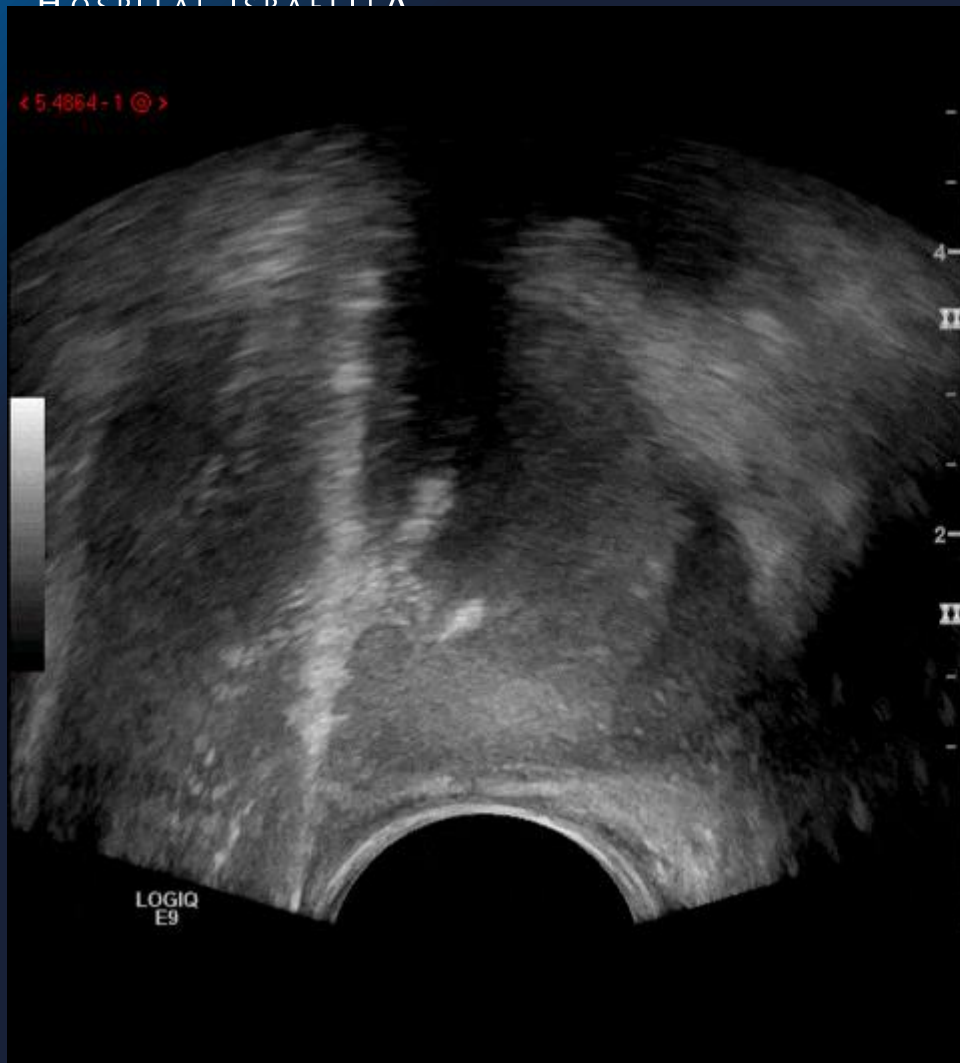


PET-RMmp com PSMA (60 minutos de exame)

D I A G N Ó S T I C O P O R I M A G E M



ALBERT EINSTEIN
HOSPITAL ISRAELITA





PEÇAS RADICAIS E PUNÇÕES

Exame Anatomopatológico

Passagem: 20534121

Dados Clínicos

Nódulo suspeito no PET com PSMA em terço médio direito anterior

Espécimes e Procedimentos

Próstata, biópsias seriadas por agulha

Microscopia e Conclusões
Diagnósticas

Adenocarcinoma acinar usual da próstata de Gleason 7 (4+3), comprometendo:
Próstata - terço médio direito: extensão linear máxima de 10,3 mm; cerca de 45% da amostra, neoplasia compromete 5 de 10 fragmentos;



Conclusão

- RMmp é o exame de escolha para detecção tumoral
 - A biópsia de próstata será sempre precedida por uma RMmp
 - RMmp irá reduzir biópsias de próstata randomizadas e desnecessárias
 - O exame de RMmp irá se tornar mais rápido, barato, acessível e inócuo
- RMmp é o exame de escolha para estadiamento local
- Estadiamento linfonodal / ósseo
 - PET/CT com ^{18}F -Fluoreto: estadiamento ósseo
 - PET/CT com ^{68}Ga -PSMA: estadiamento ósseo e linfonodal
- *Detecção, estadiamento local, linfonodal e a distância*
 - *PET/RM com ^{68}Ga -PSMA (multiparamétrica + molecular)*



ALBERT EINSTEIN
HOSPITAL ISRAELITA

Obrigado!